

DDS Filippo Cardarelli
Dentist
Specialist in Orthodontics
University of Milan



1st Class Deepbite

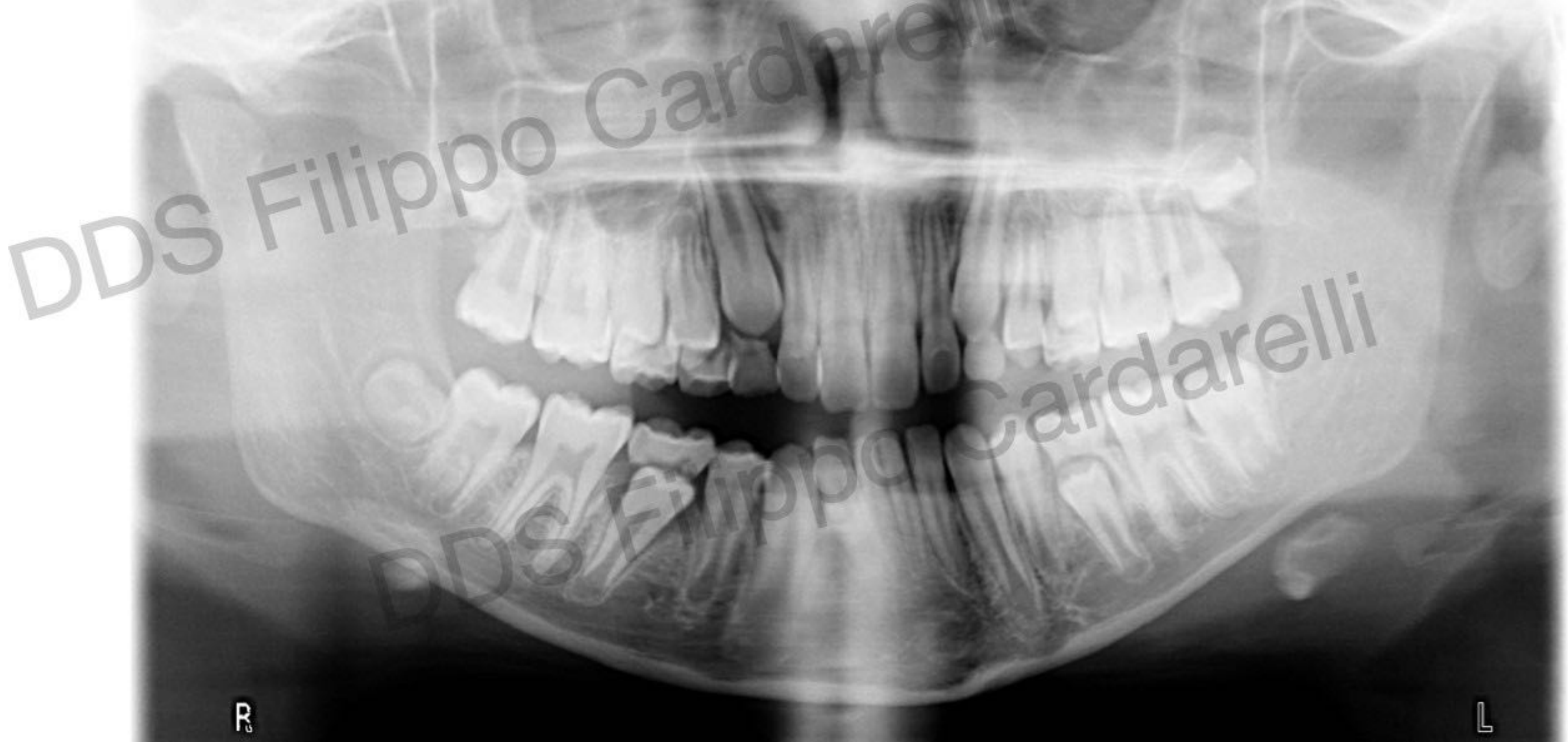9-year-old patient deep bite dental and skeletal. Malocclusion is characterized by contraction of the upper arch with reduced space for eruption of permanent teeth.

The therapeutic sequence involves the following steps:

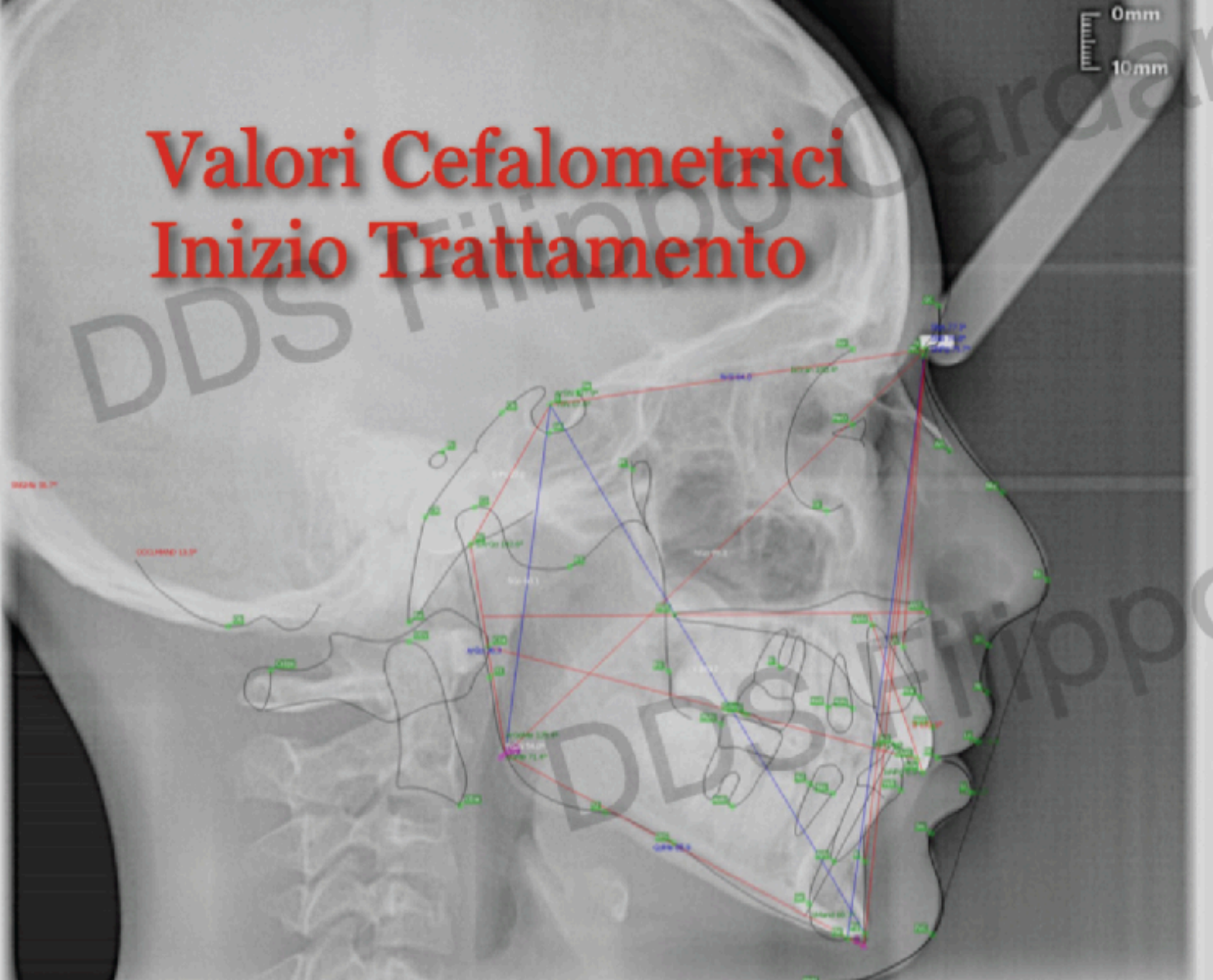
- Motivation
- Elastodontic therapy (duration 14 months)

S. Filippo Cardarelli



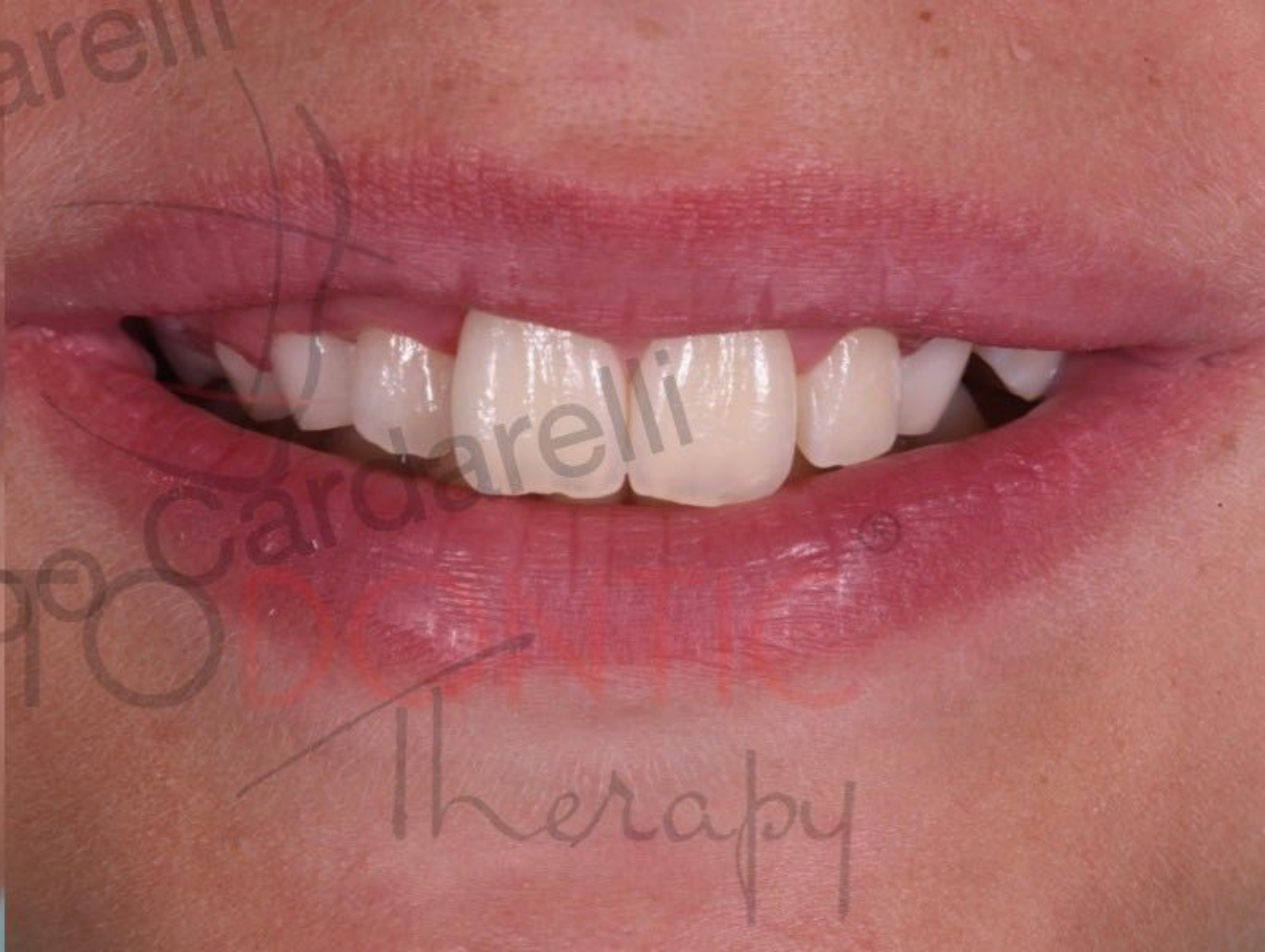
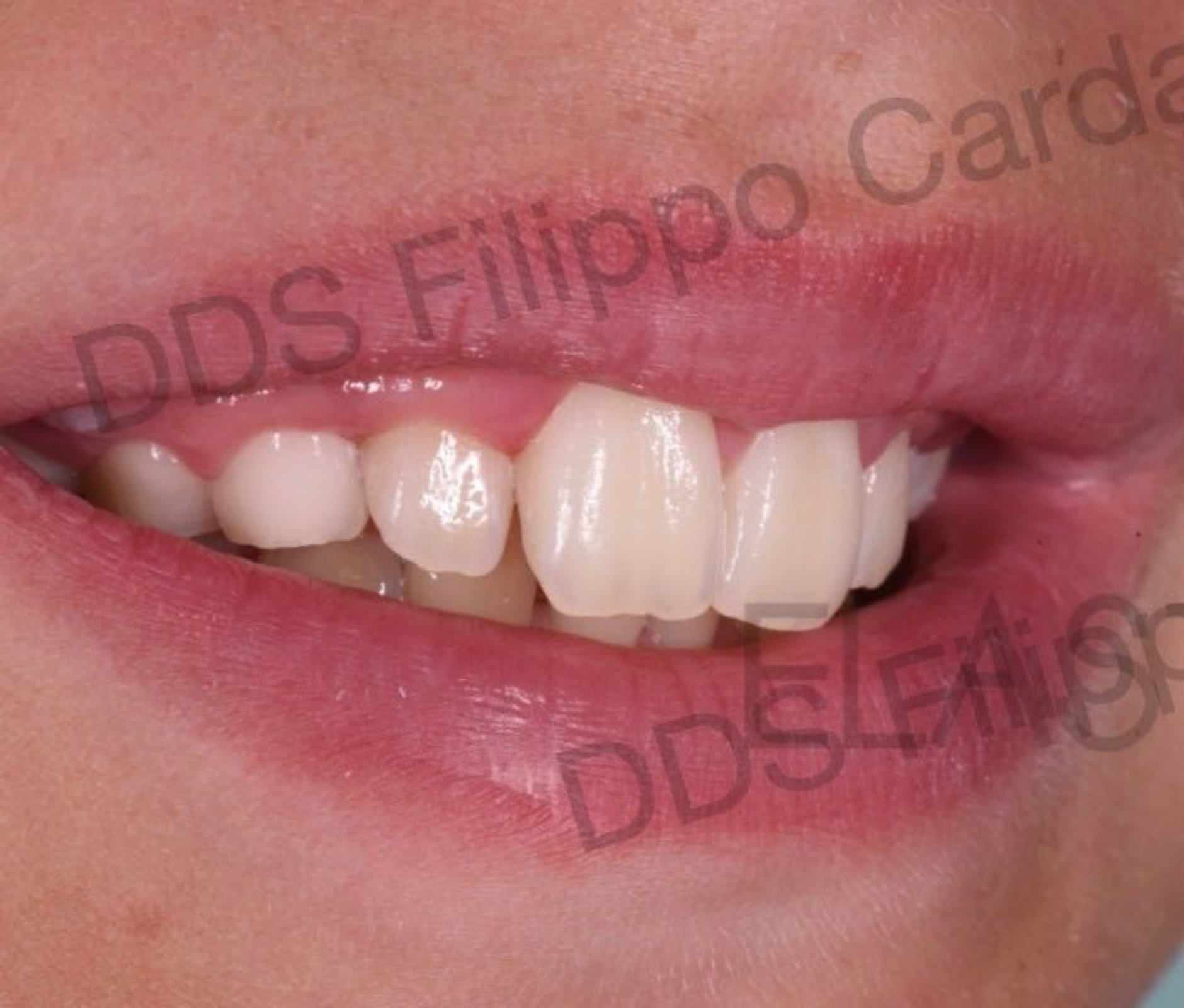
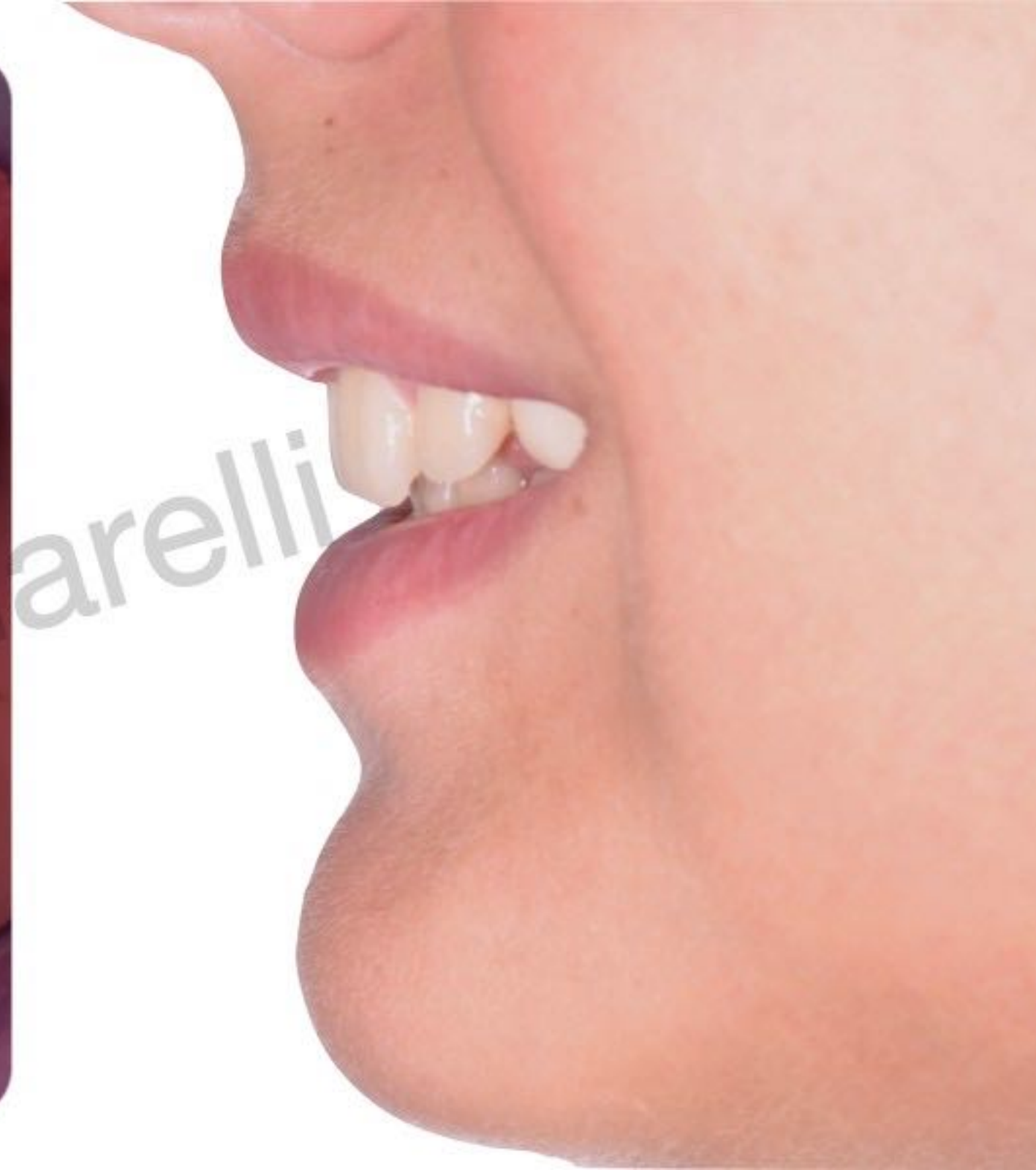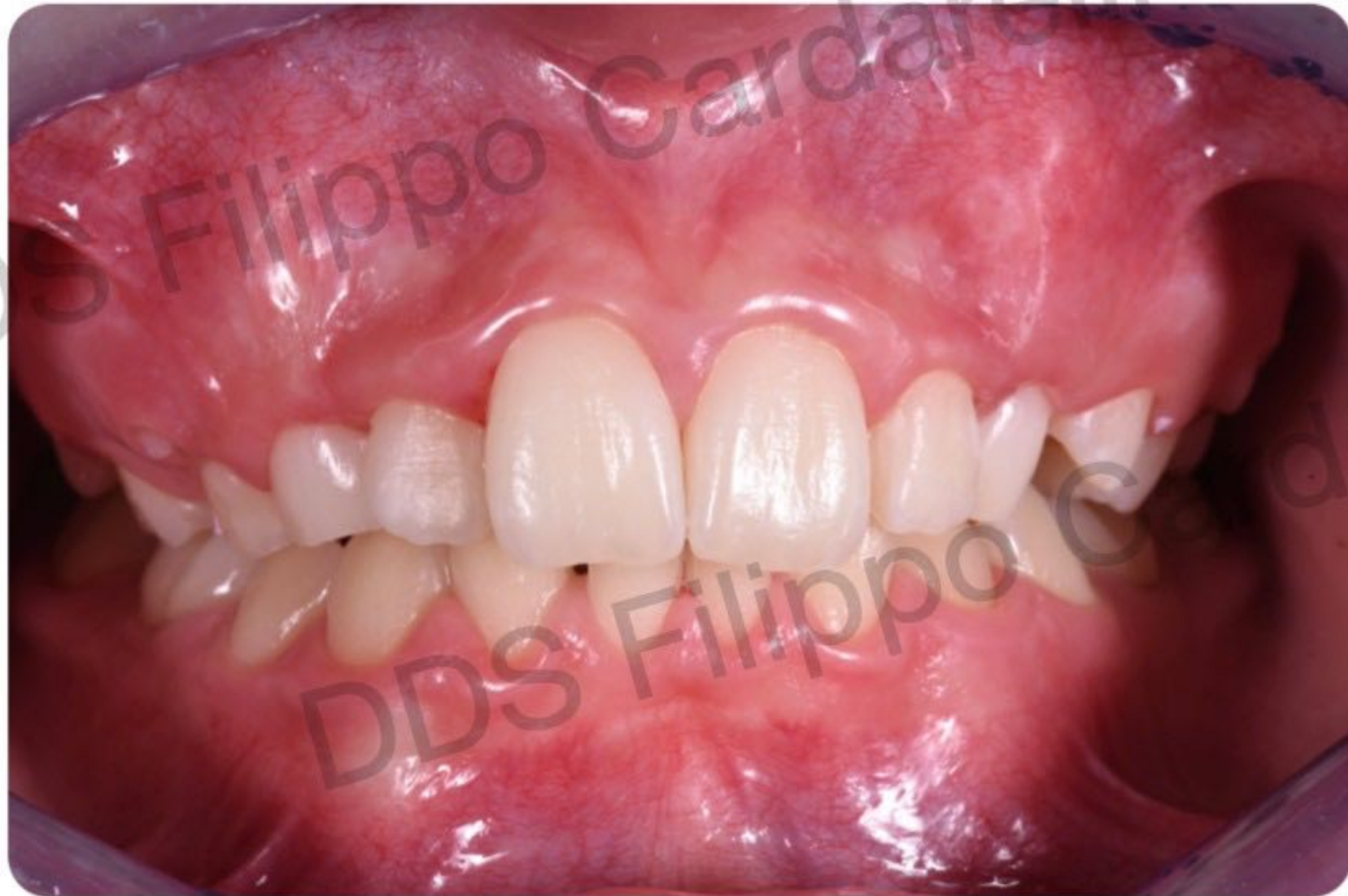Valori Cefalometrici Inizio Trattamento

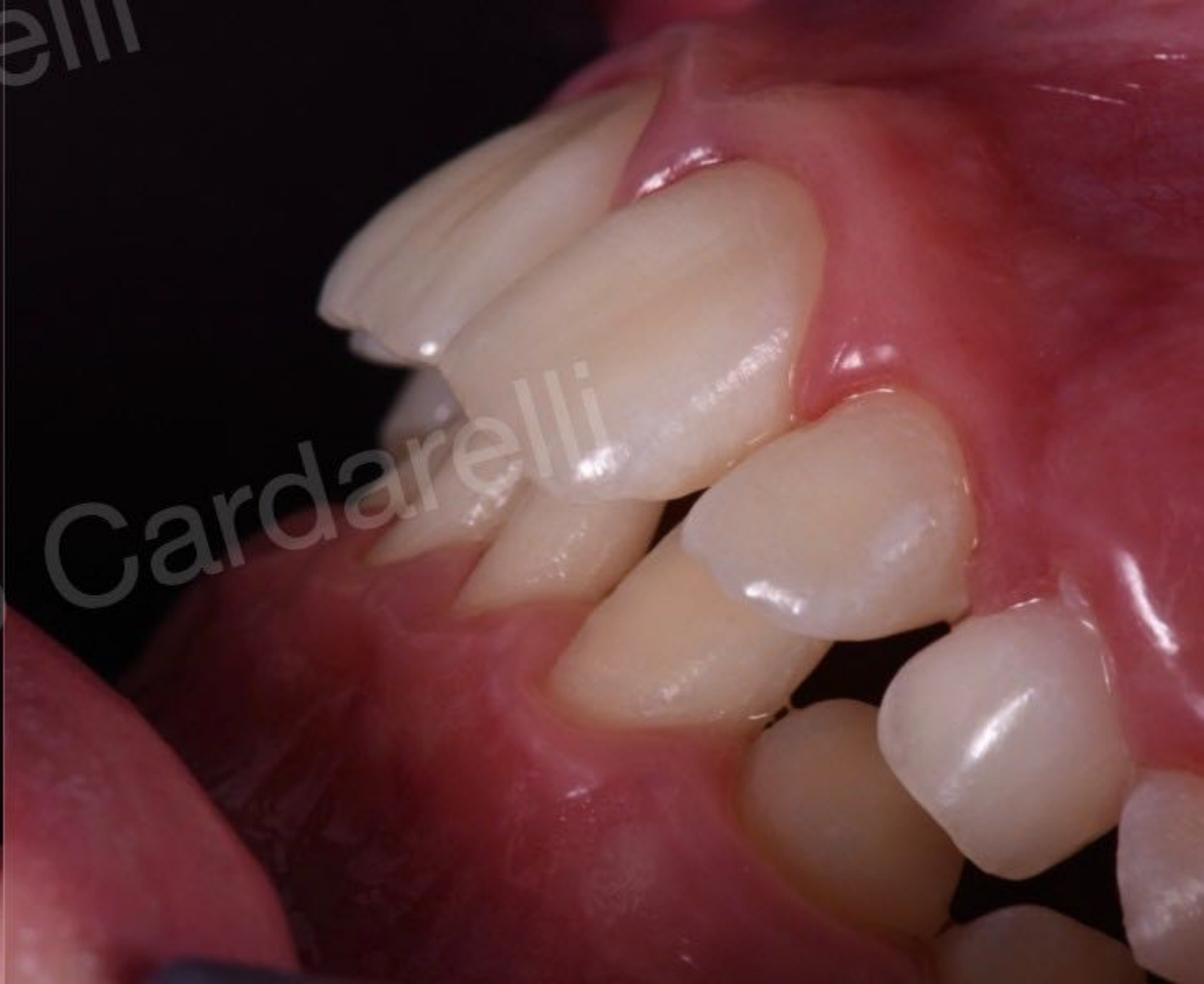
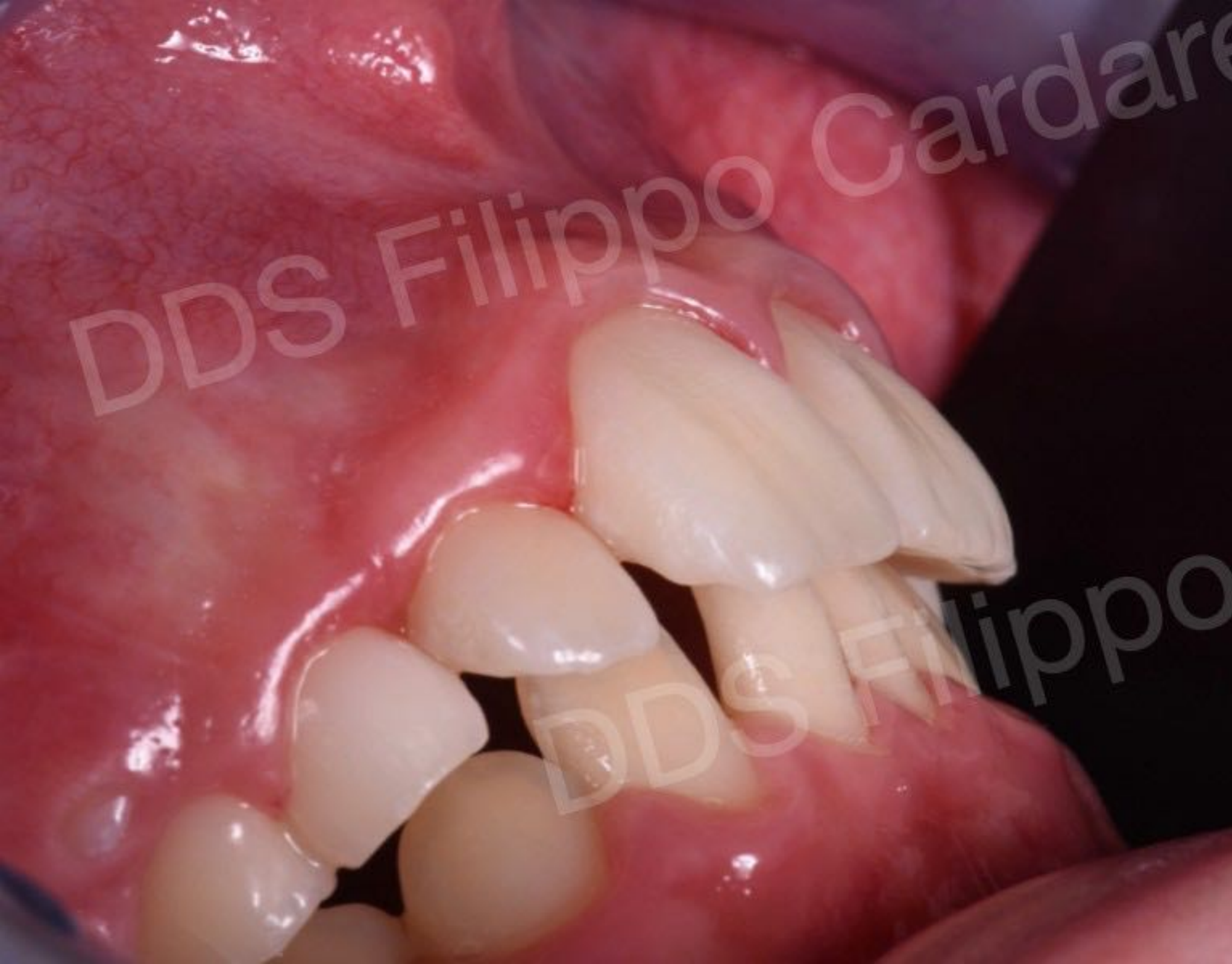
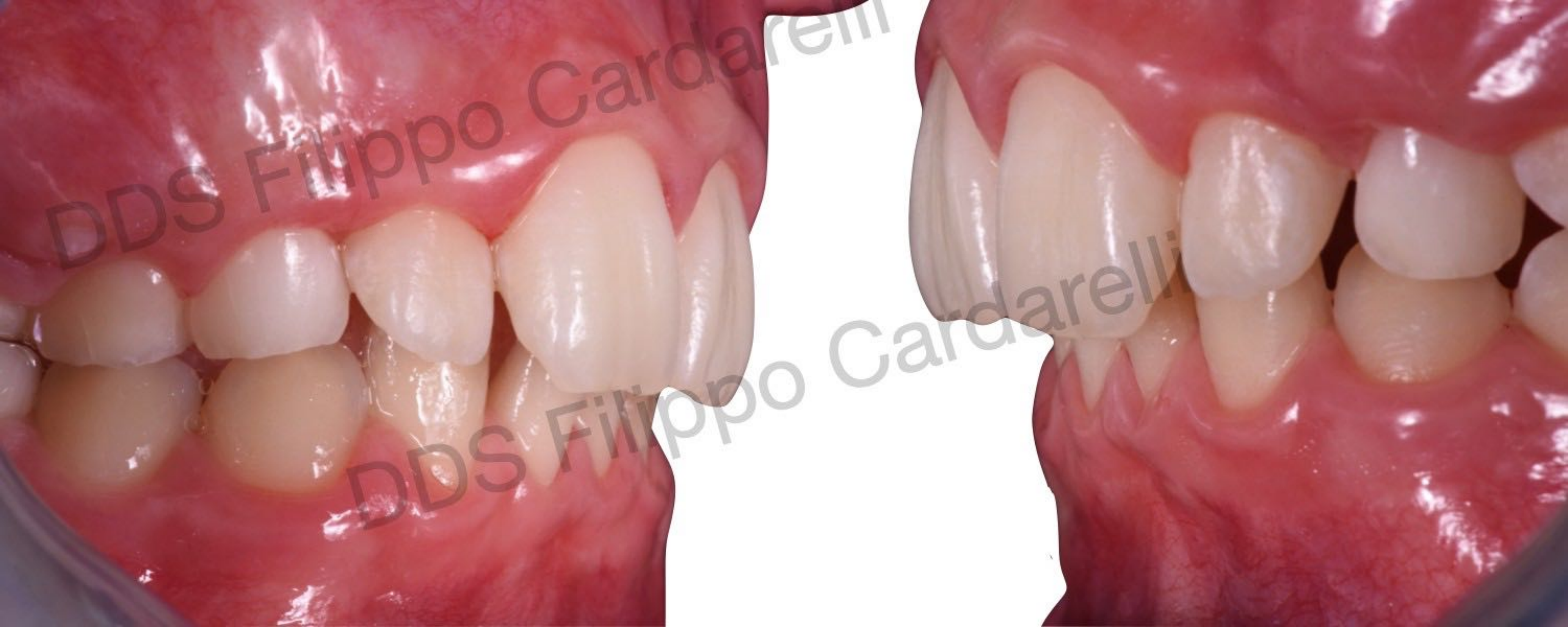Cephalometric values Start of Treatment

ANB	2,5
SNA	77,30
SNB	74,80
SArGo	142,00
ArGoMe	125,00
IiMand	89,20
IsCran	100,00
II	133,00









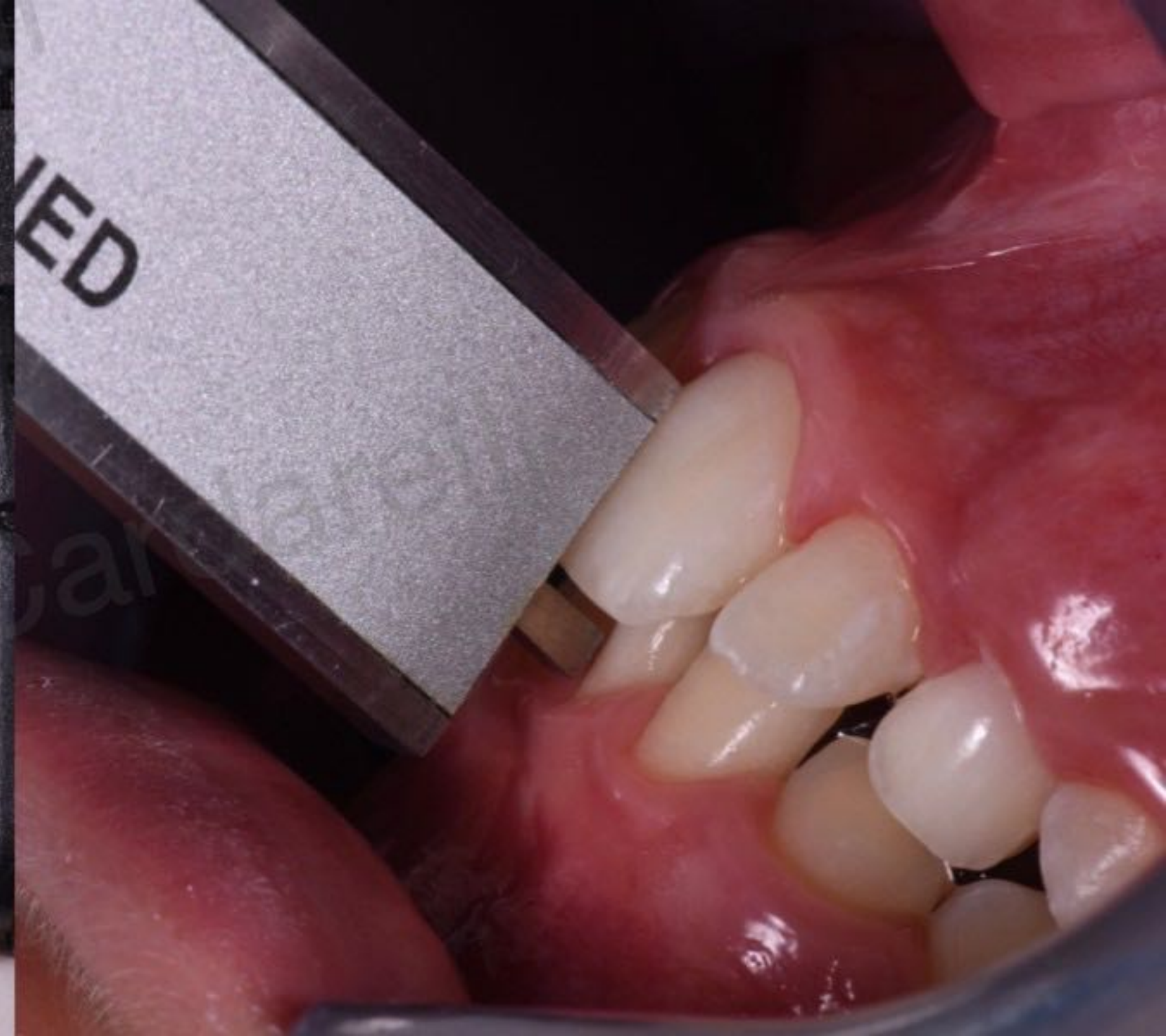
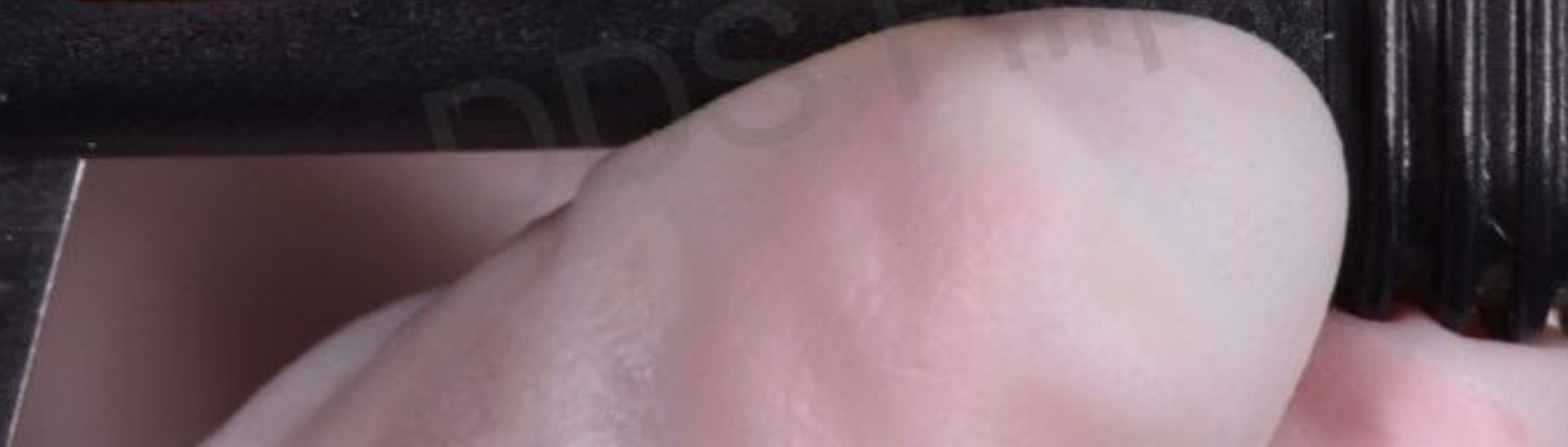 inch/mm

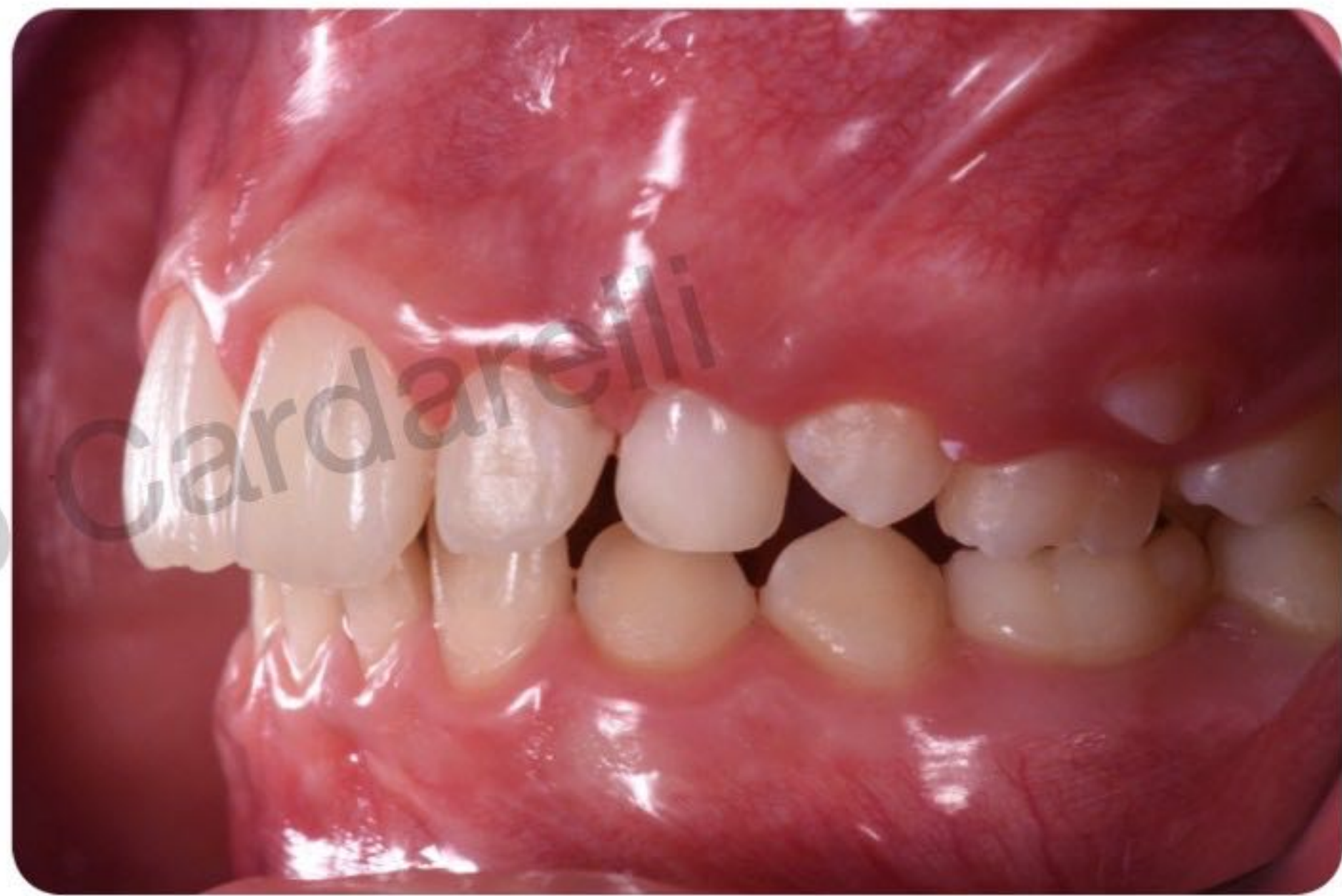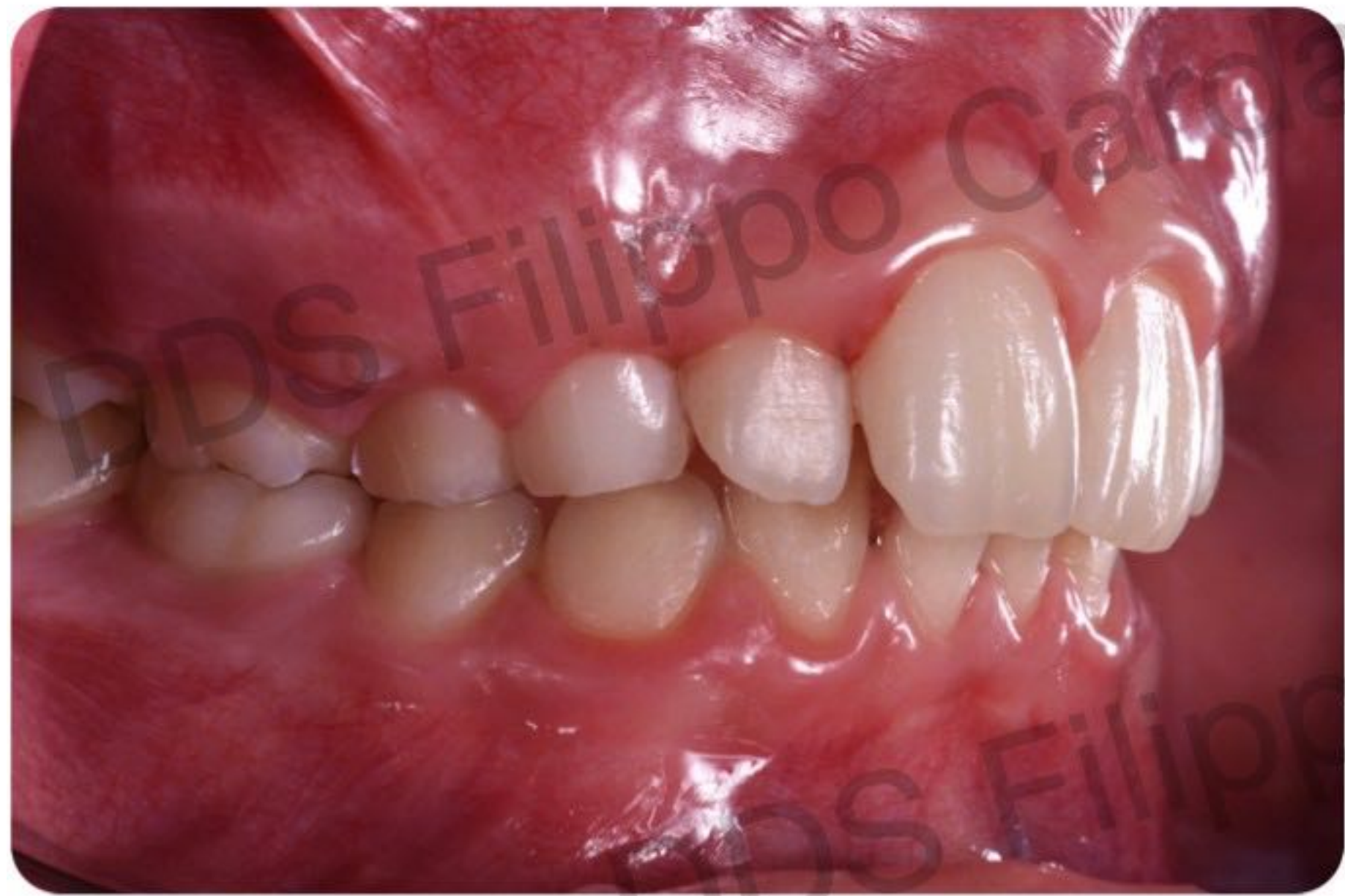4.40 mm

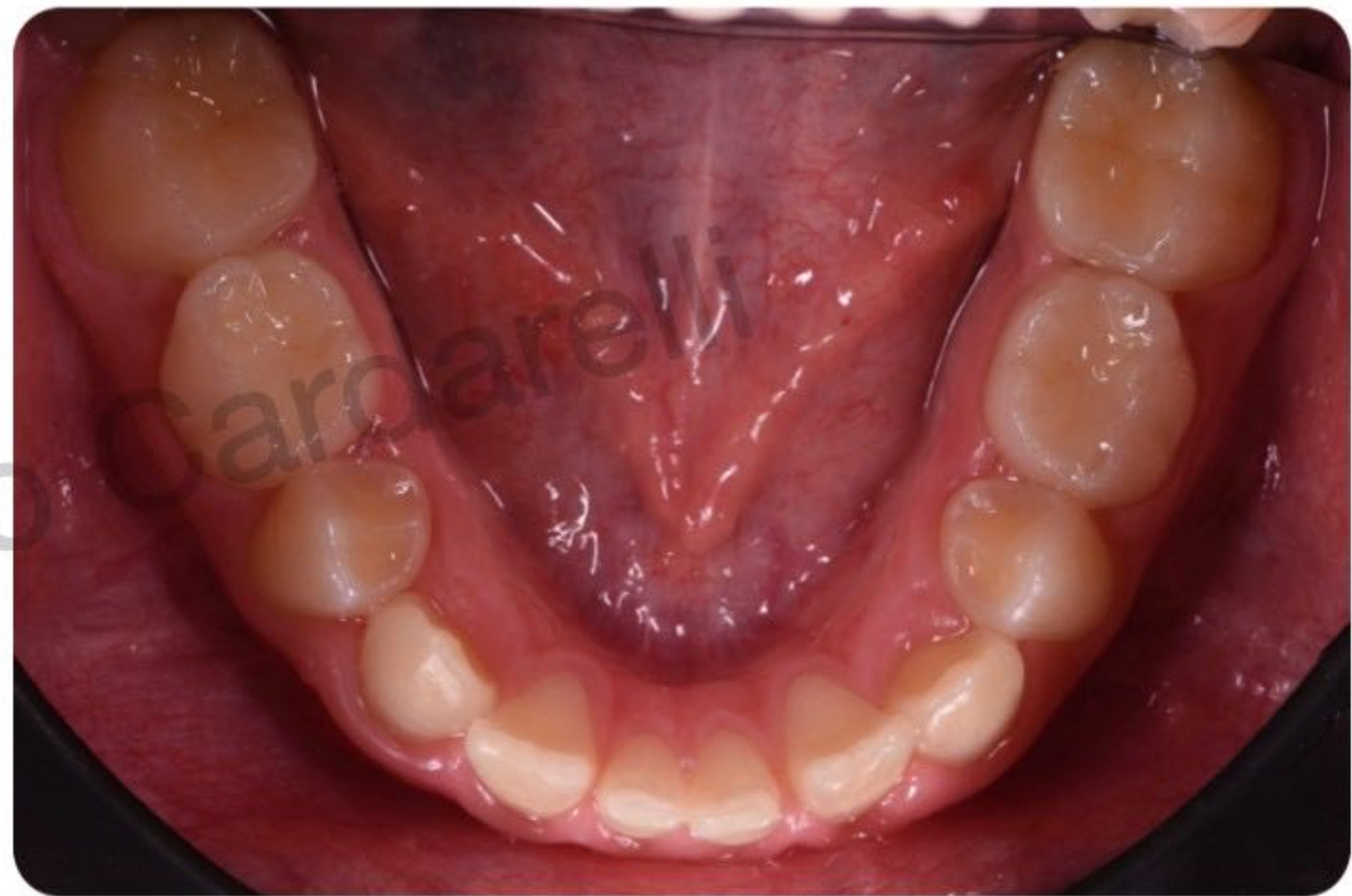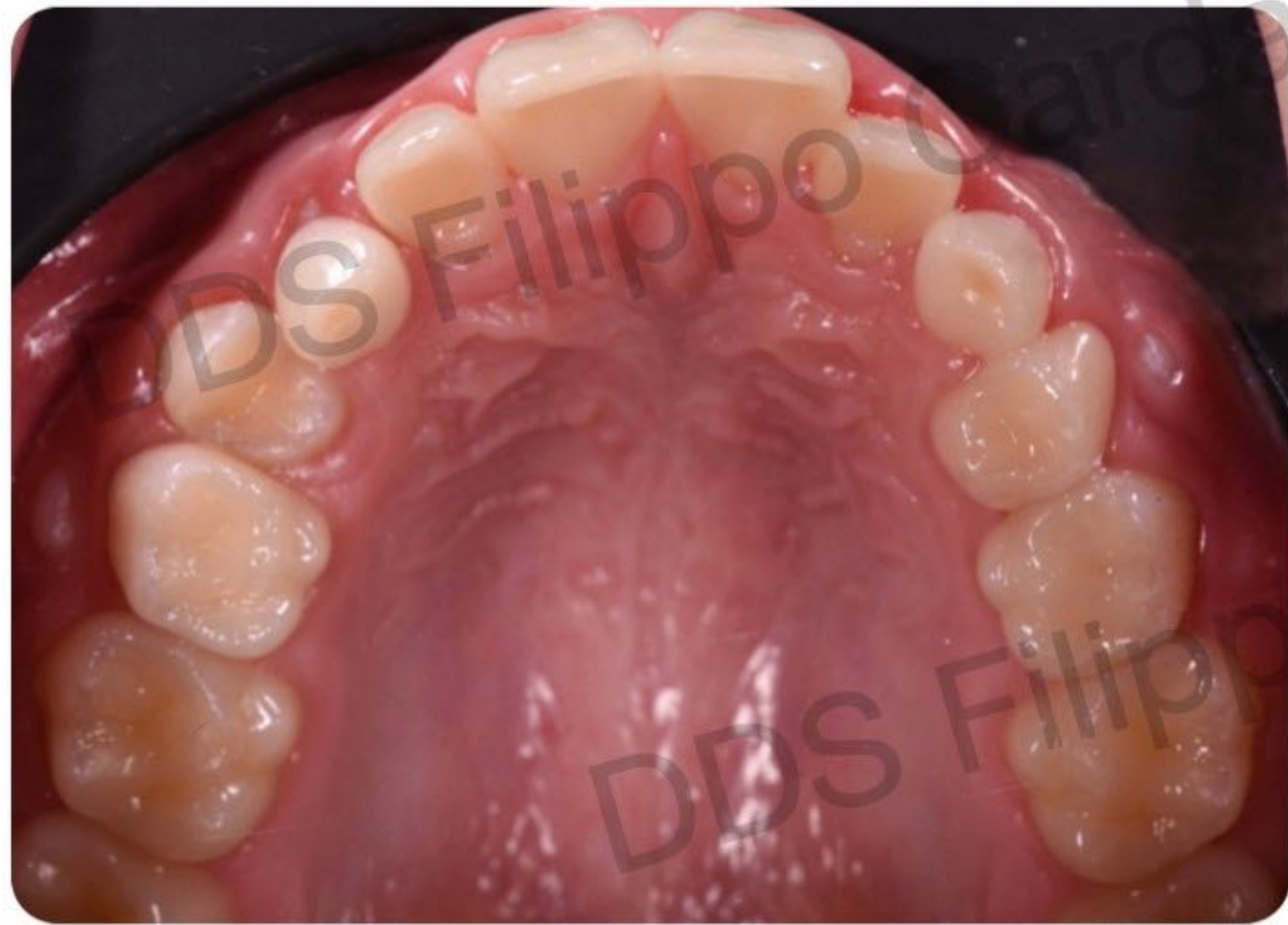OFF  ON

 ZERO

LED







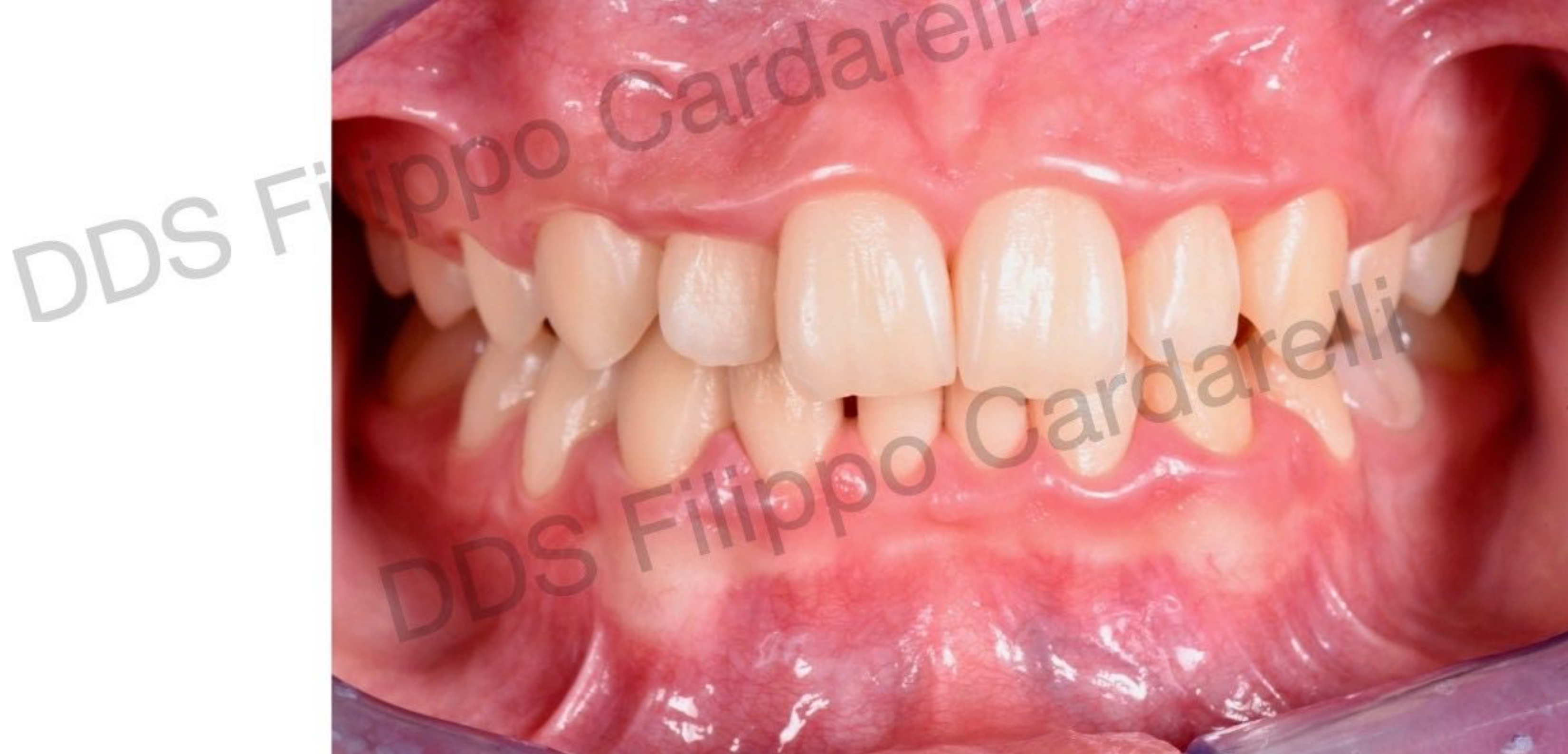1st Step



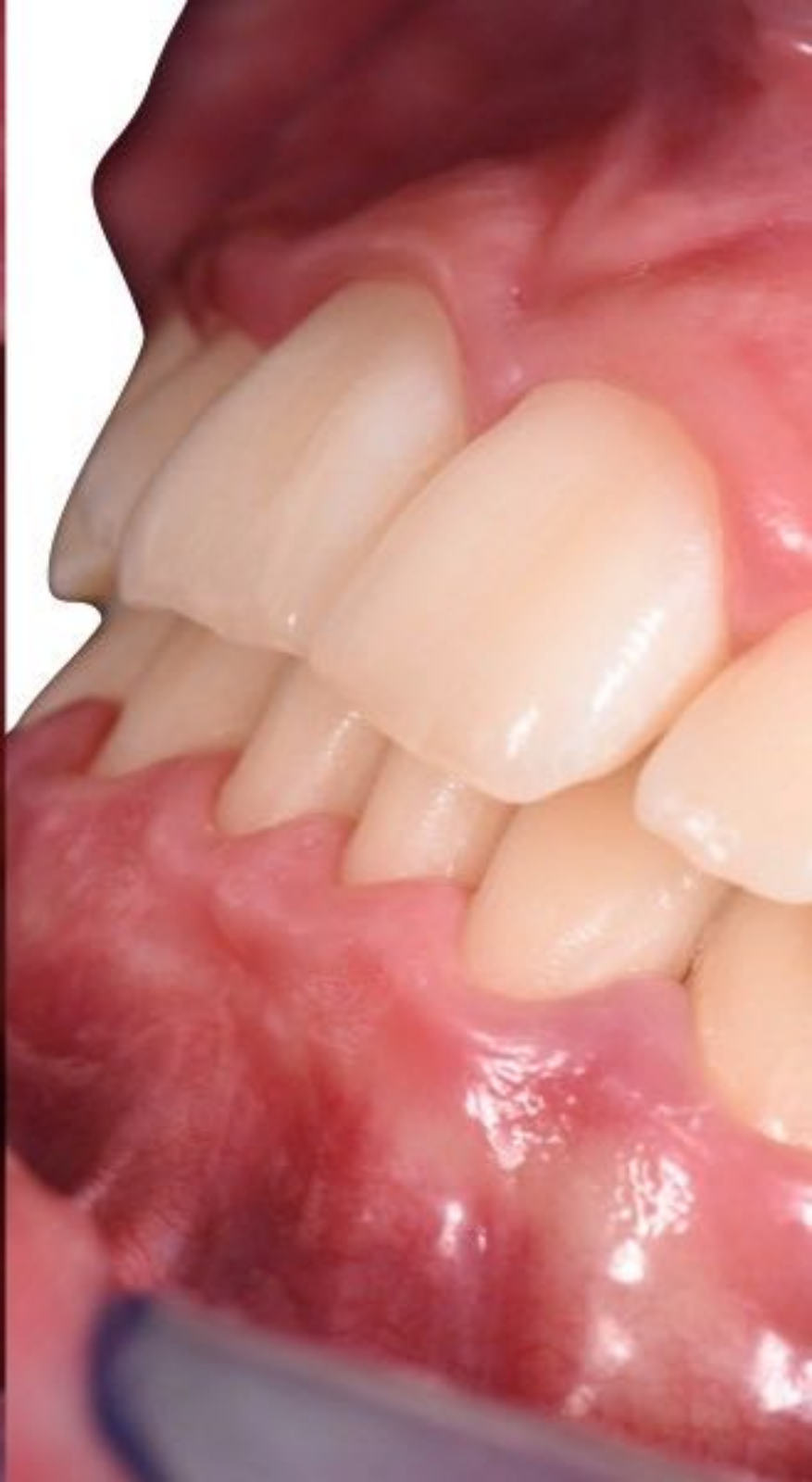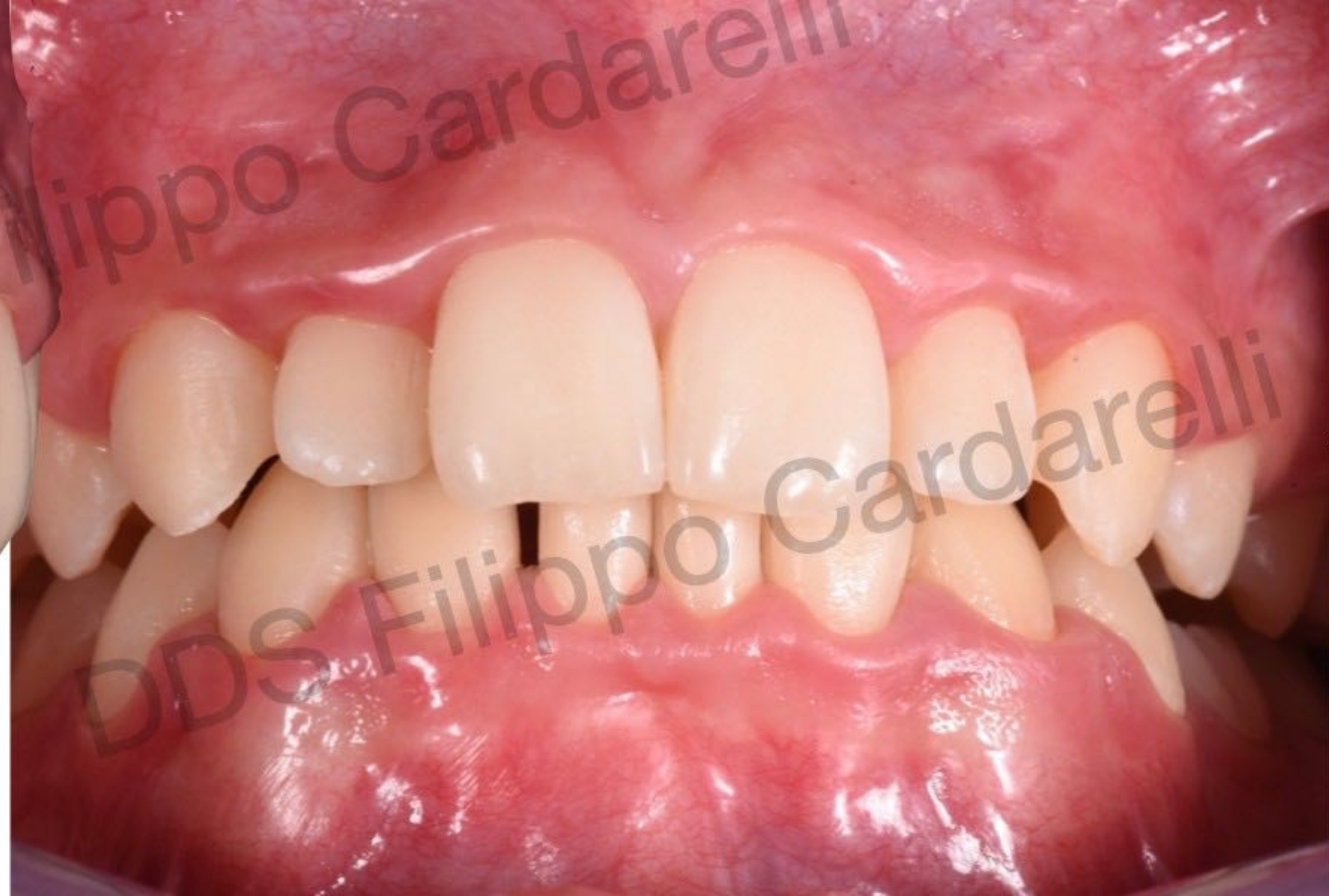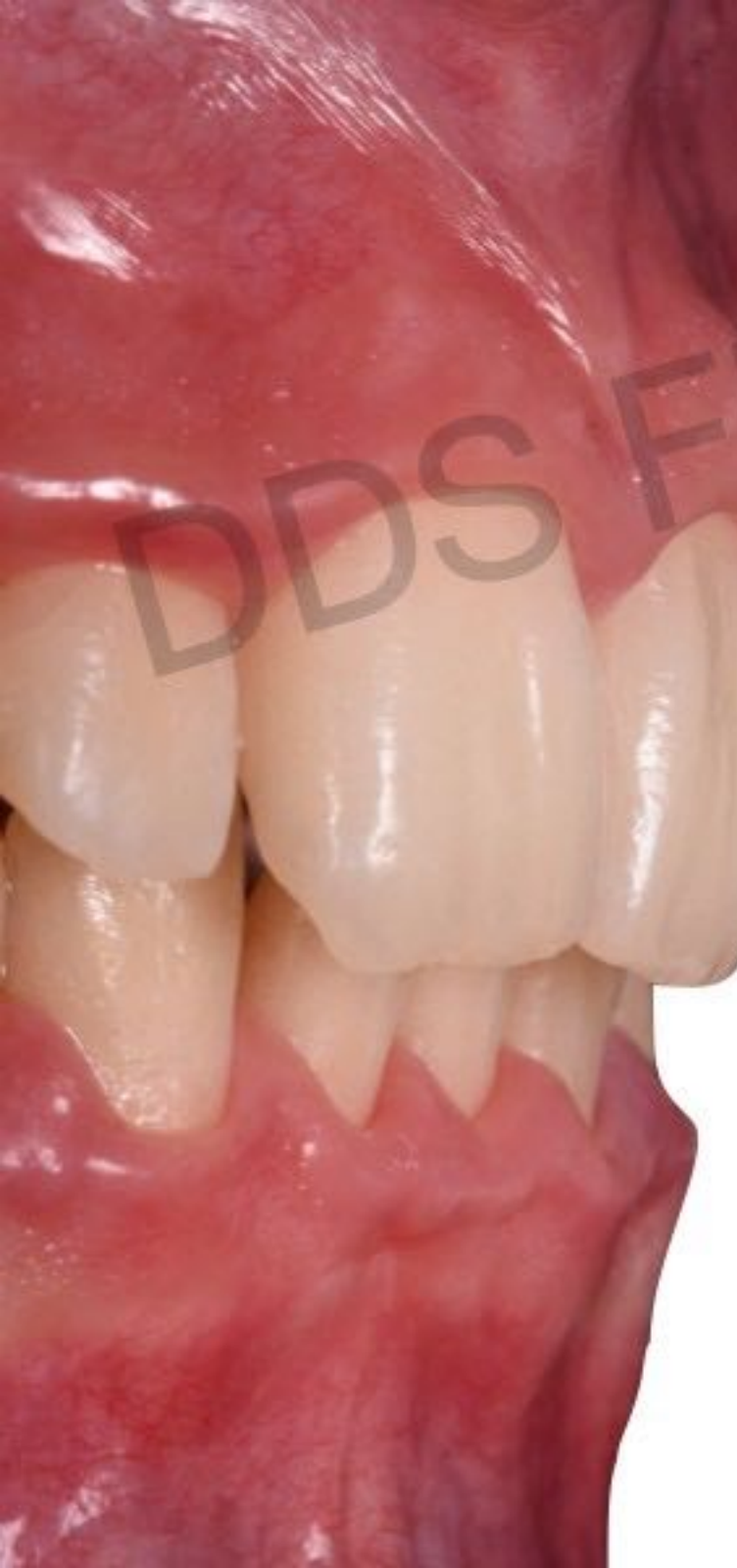The elastodontic appliance used was the AMCOP Integral with the purpose of expanding the upper arch and coordinating the arches.

Use was one hour during the day and every night for 6 months and then for another 8 months only at night.

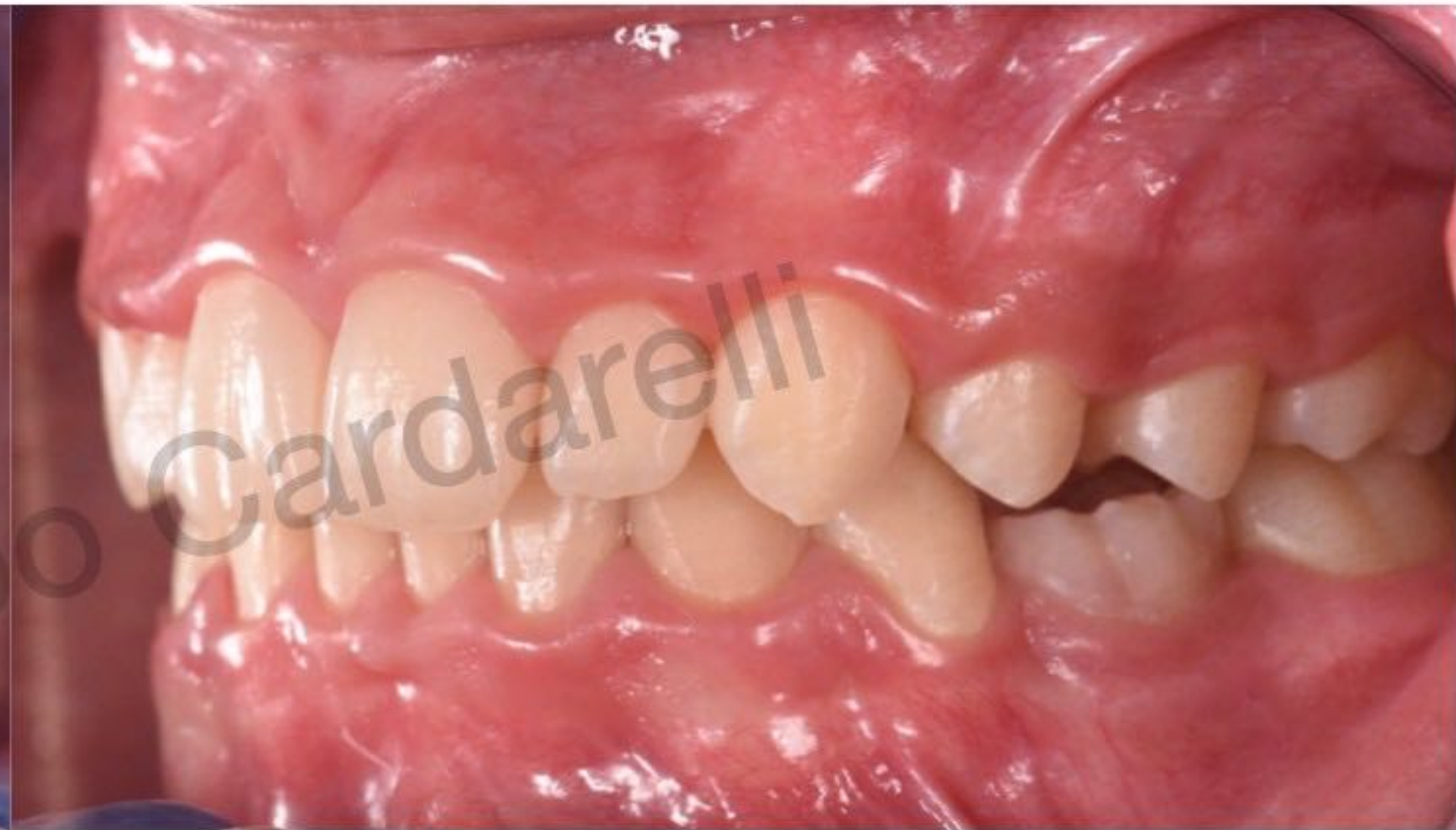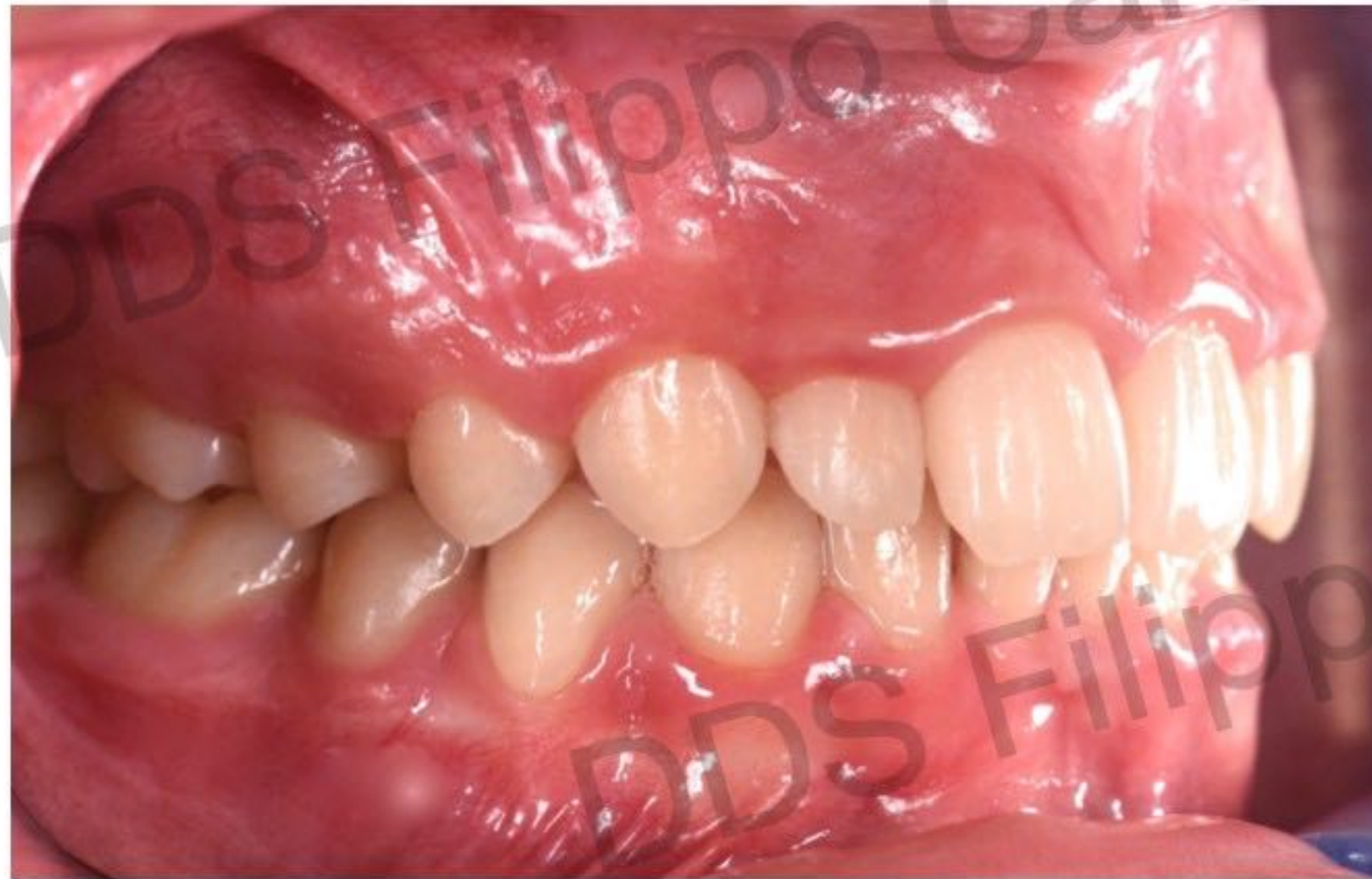S. Filippo Cardarelli



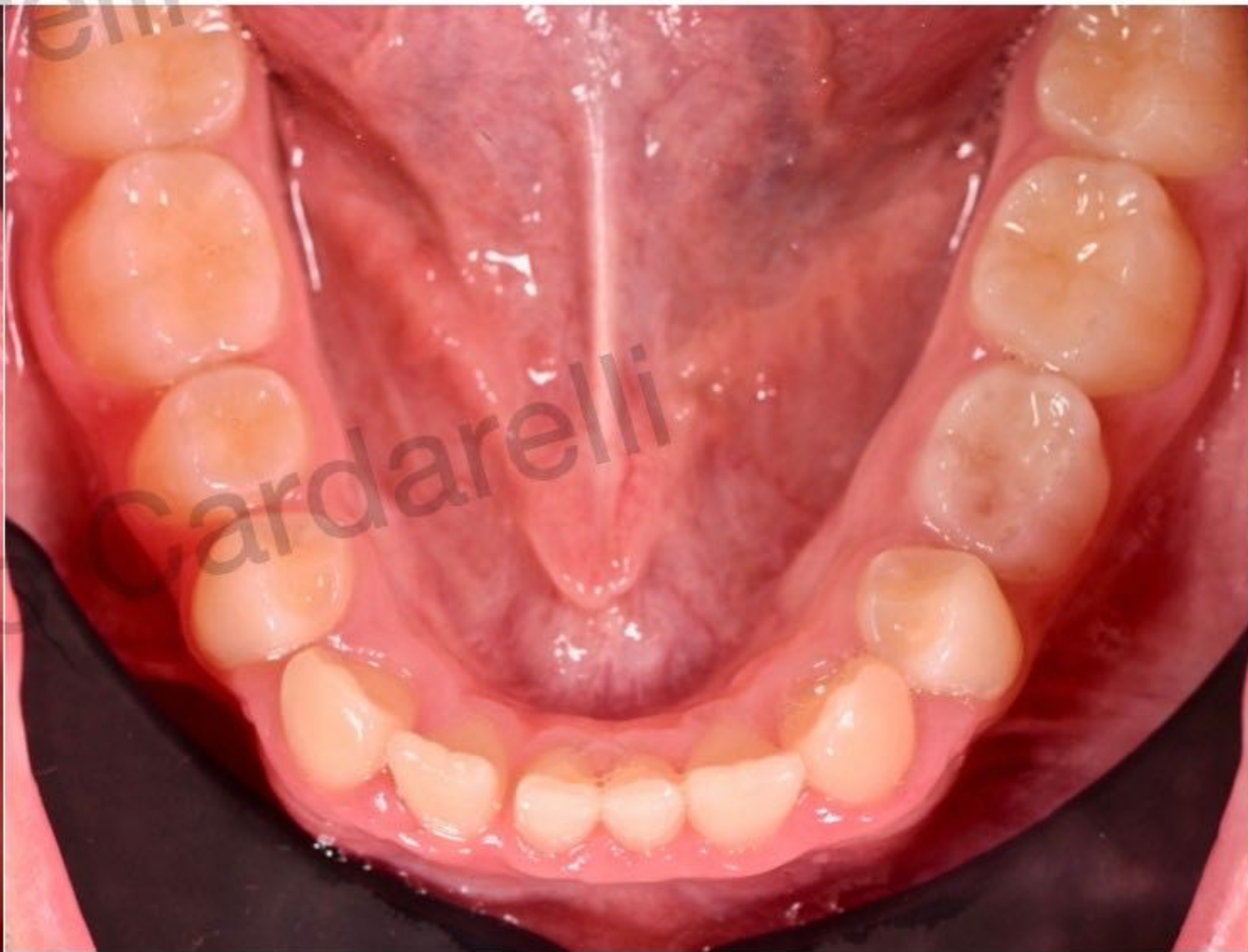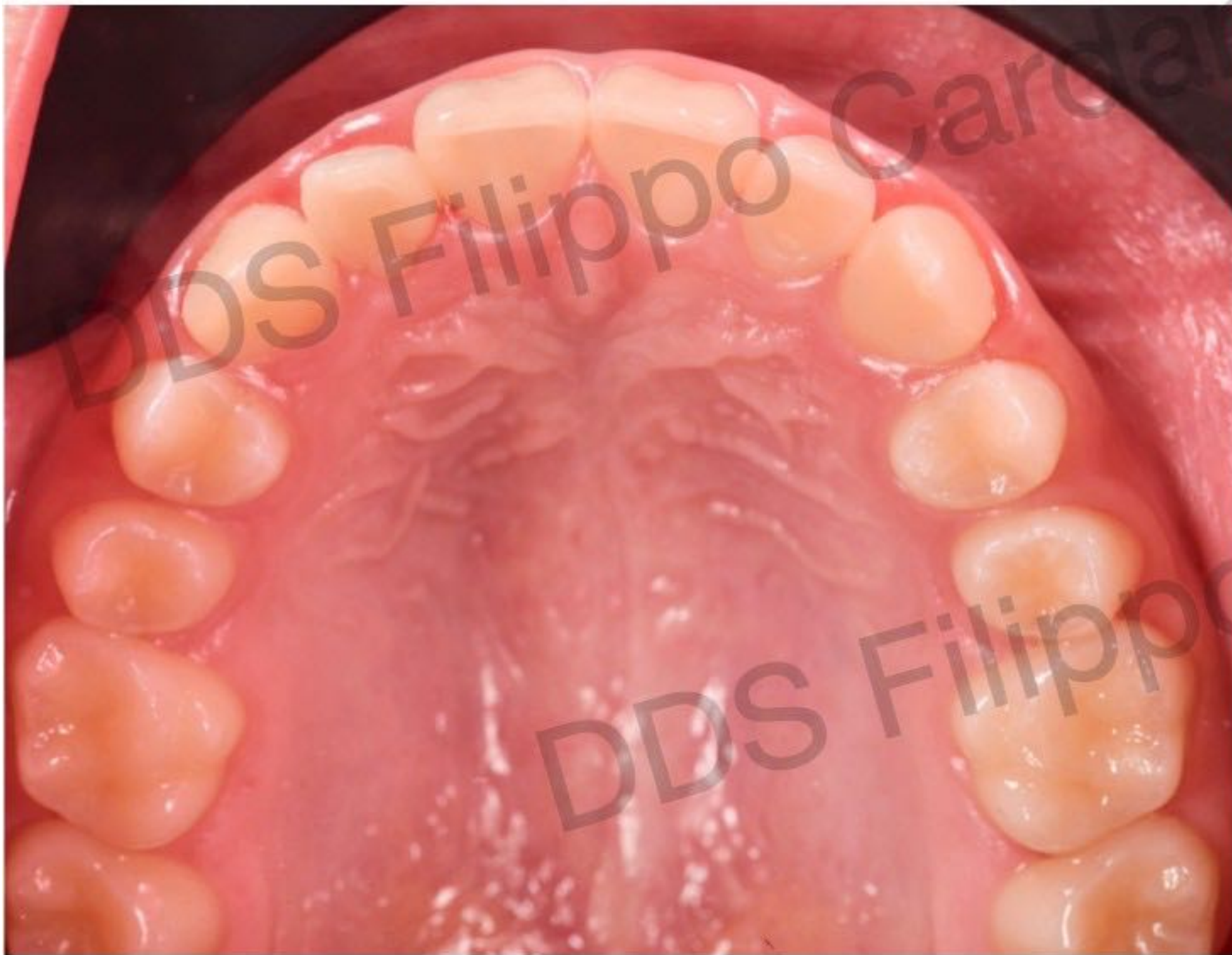*12 months
check*



DDS Filippo Cardarelli



DDS Filippo Cardarelli



Valori Cefalometrici Intermedi

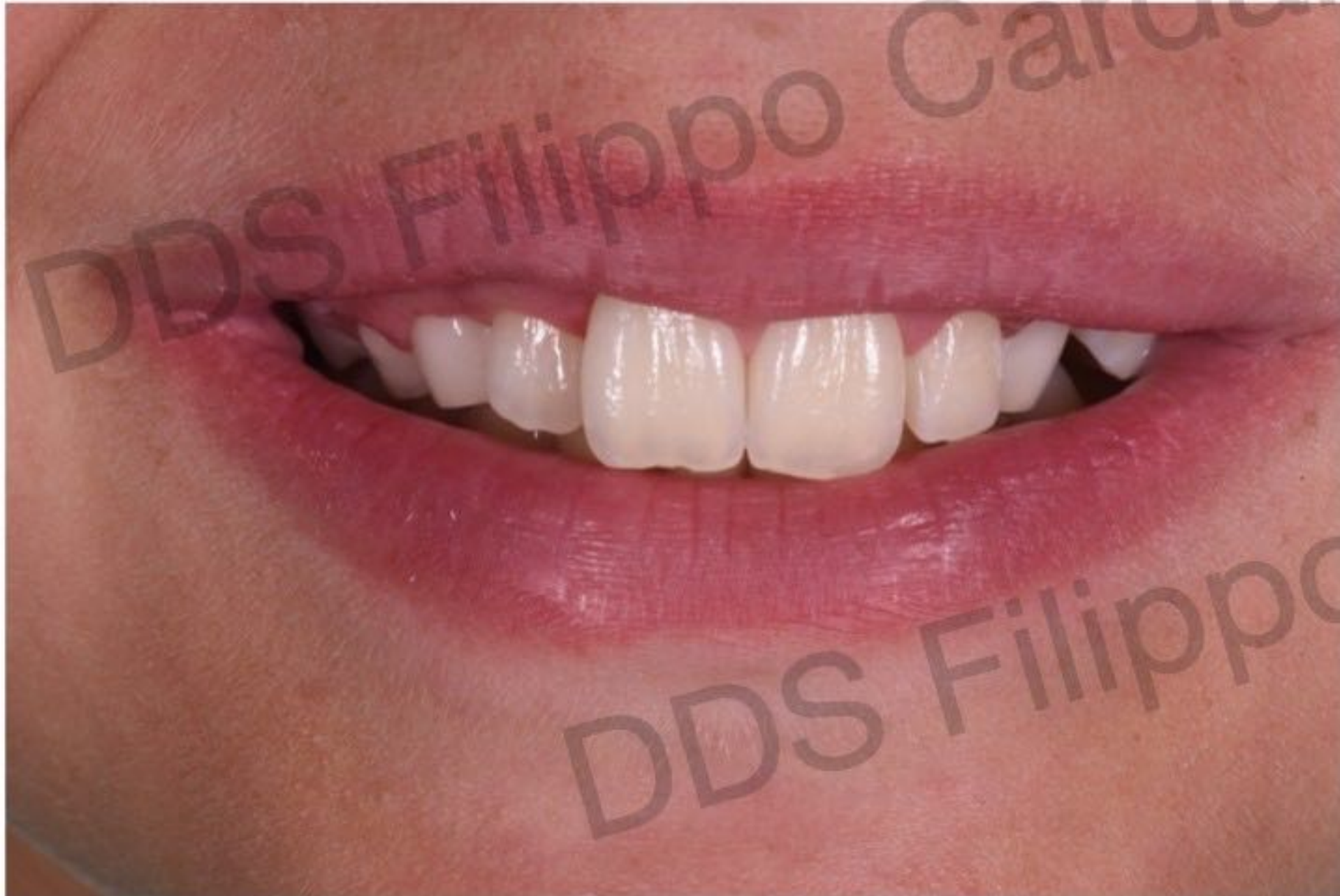0mm
10mm

Intermediate Cephalometric Values

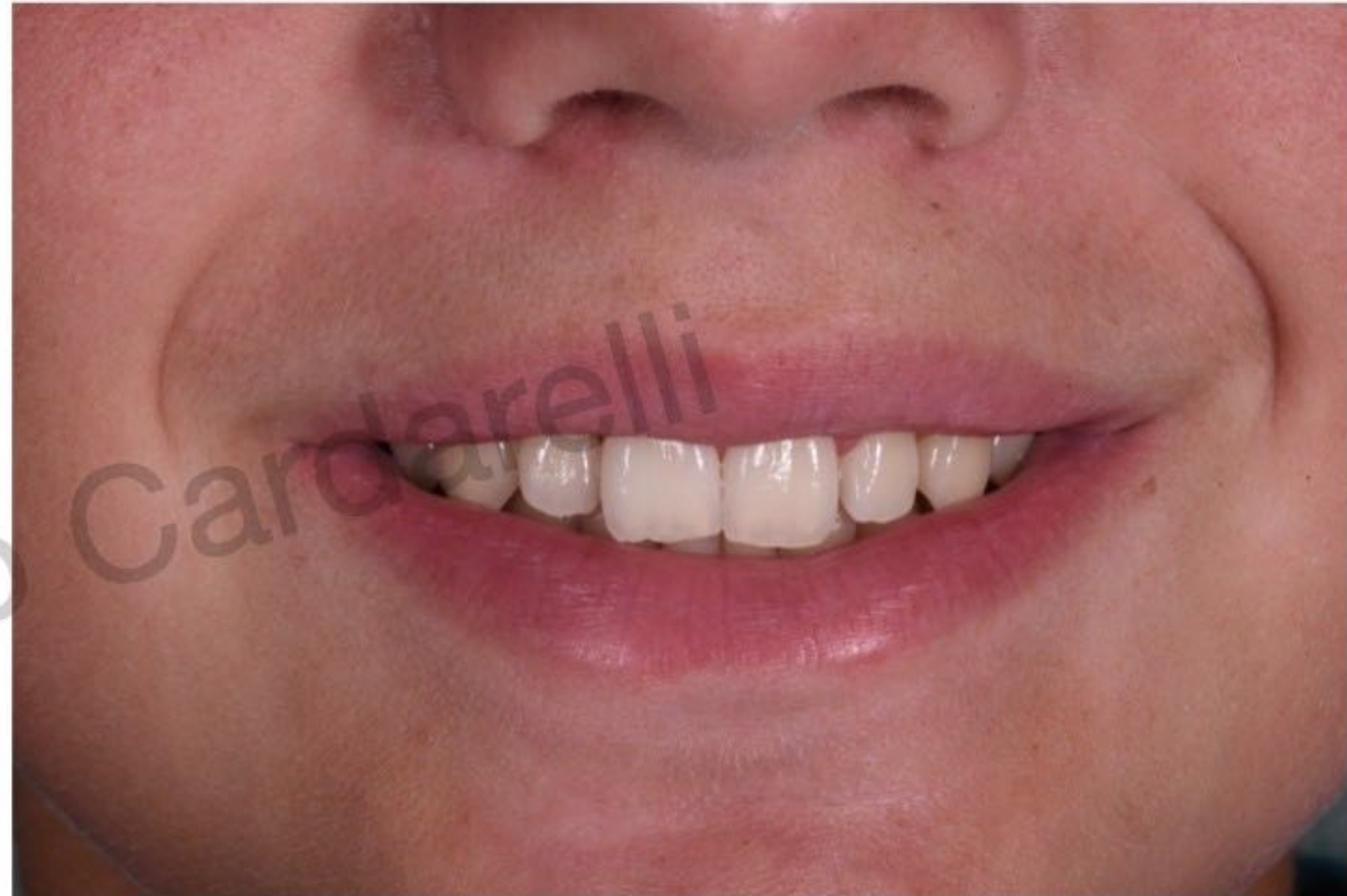ANB	3,0	2,5
SNA	80,00	77,30
SNB	77,00	74,80
SArGo	146,00	142,0
ArGoMe	125,00	125,00
IiMand	87,20	89,20
IsCran	98,00	100,00
II	130,00	133,00

Ctr 08/17

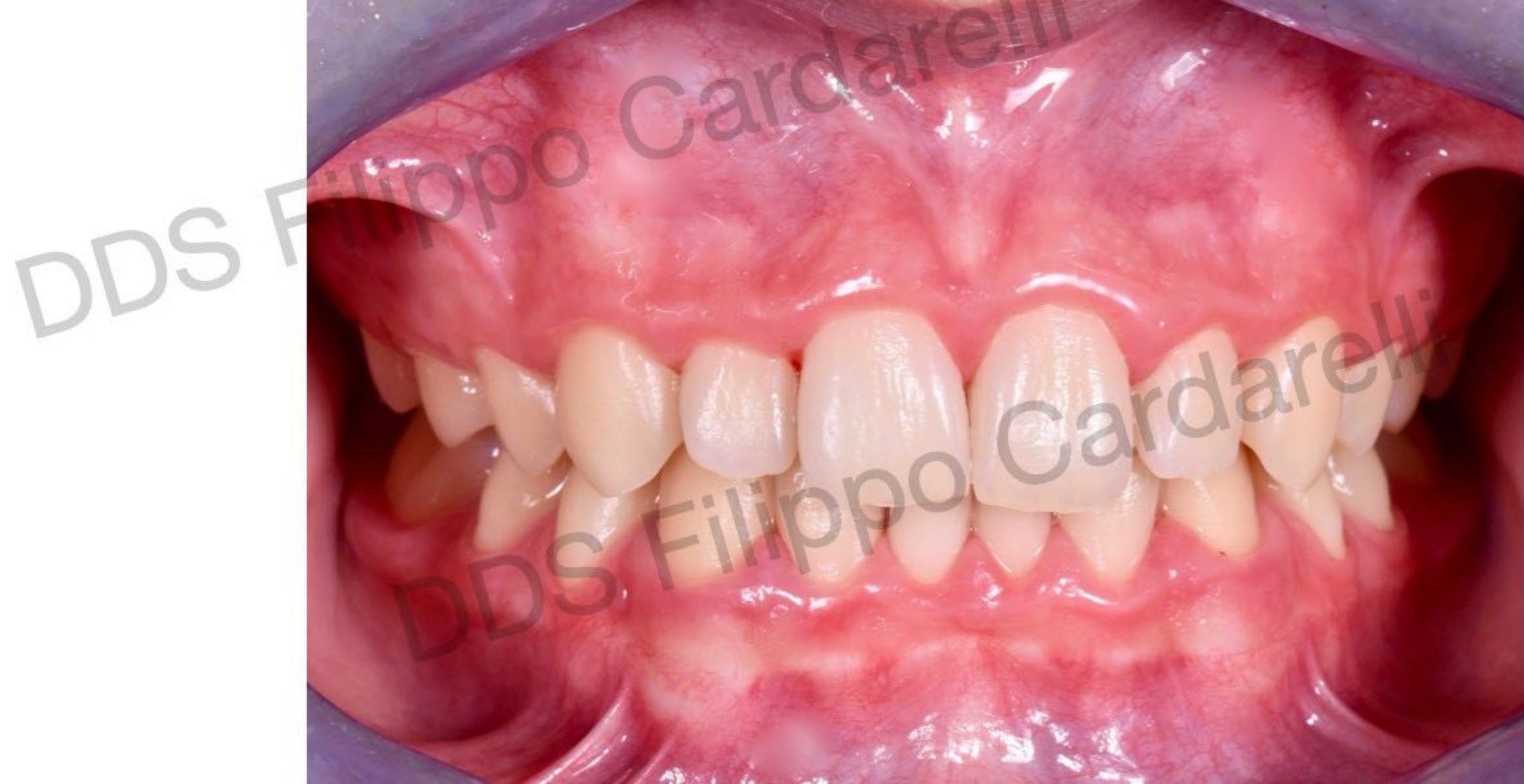


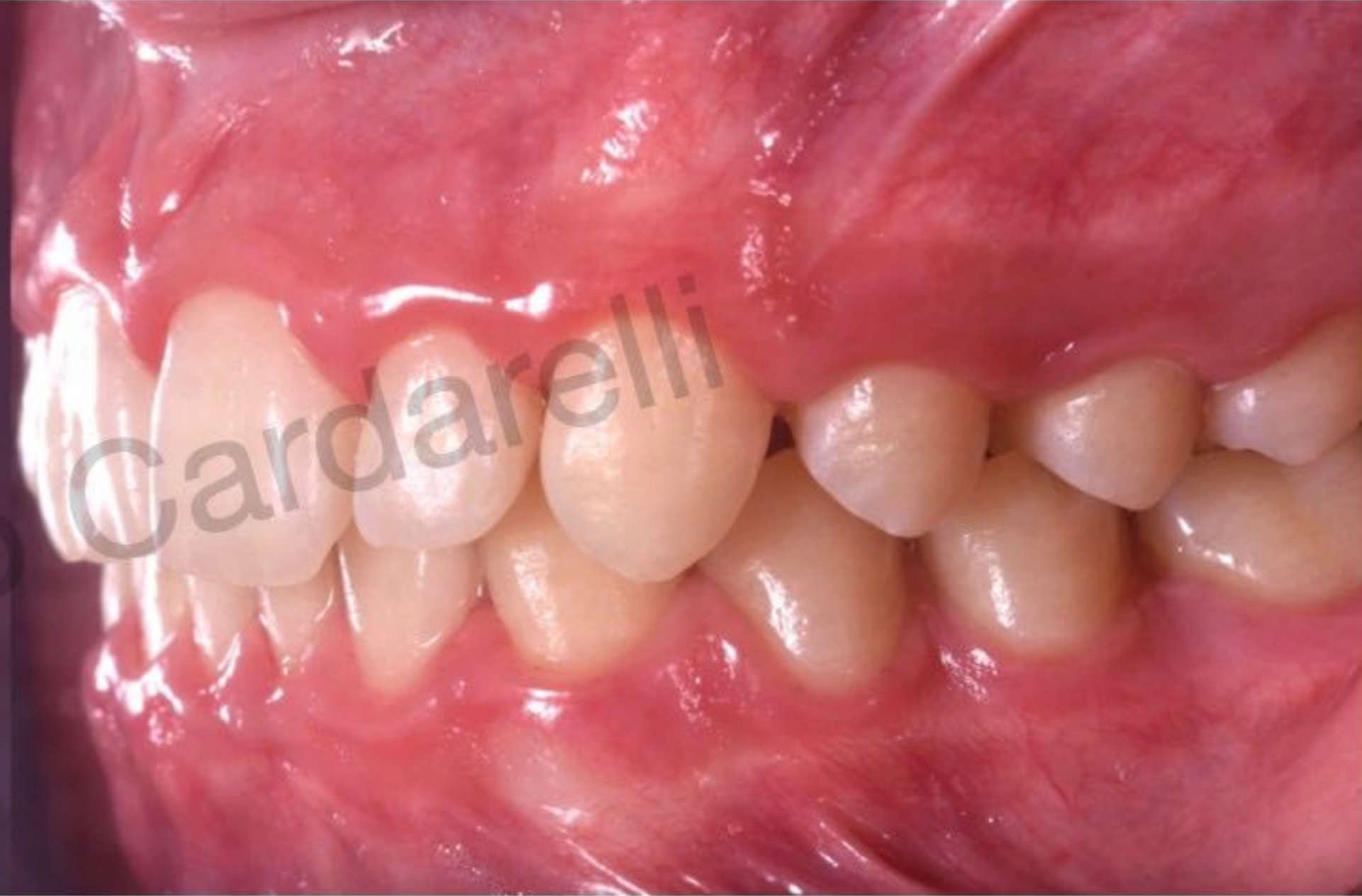
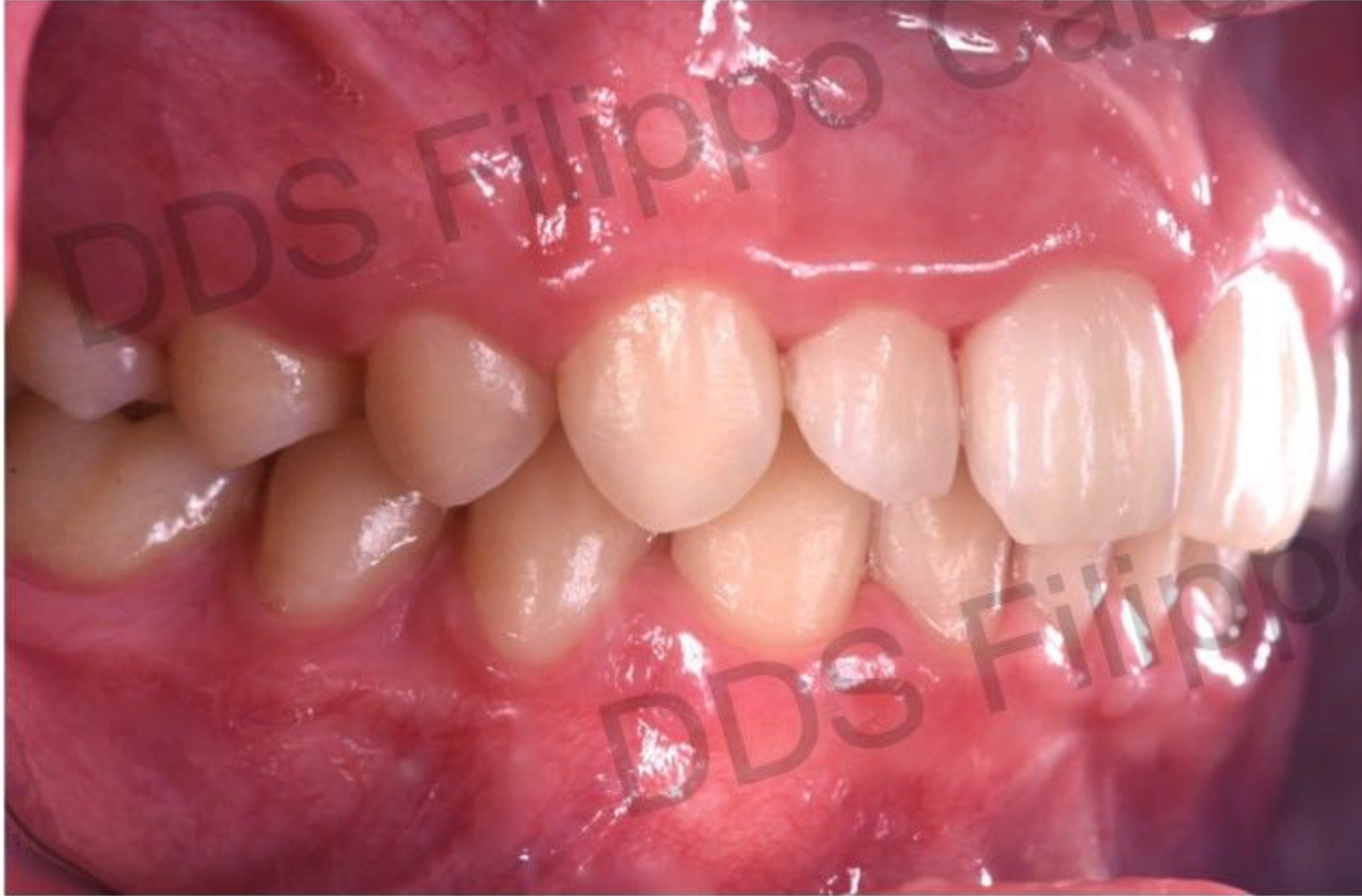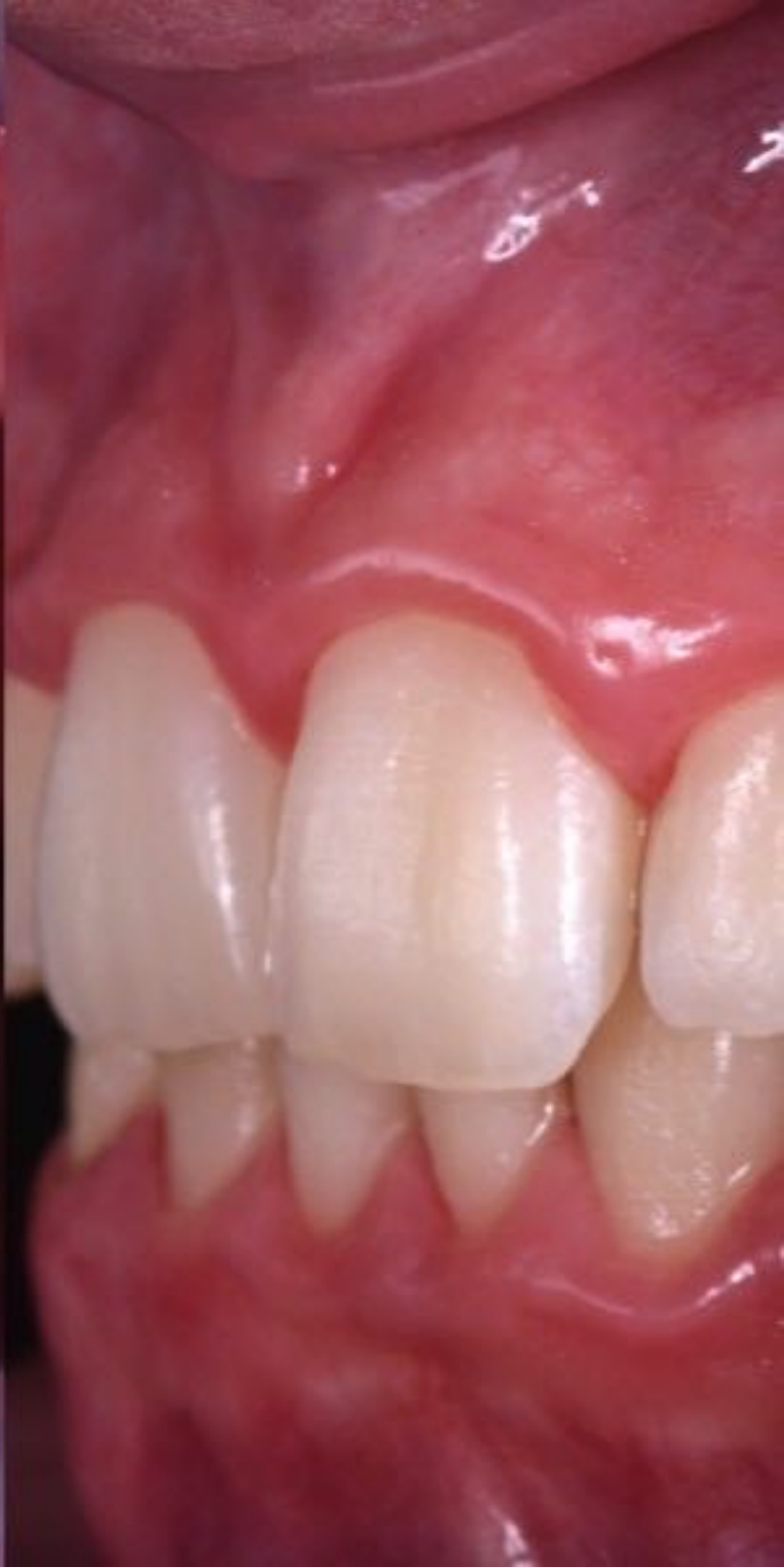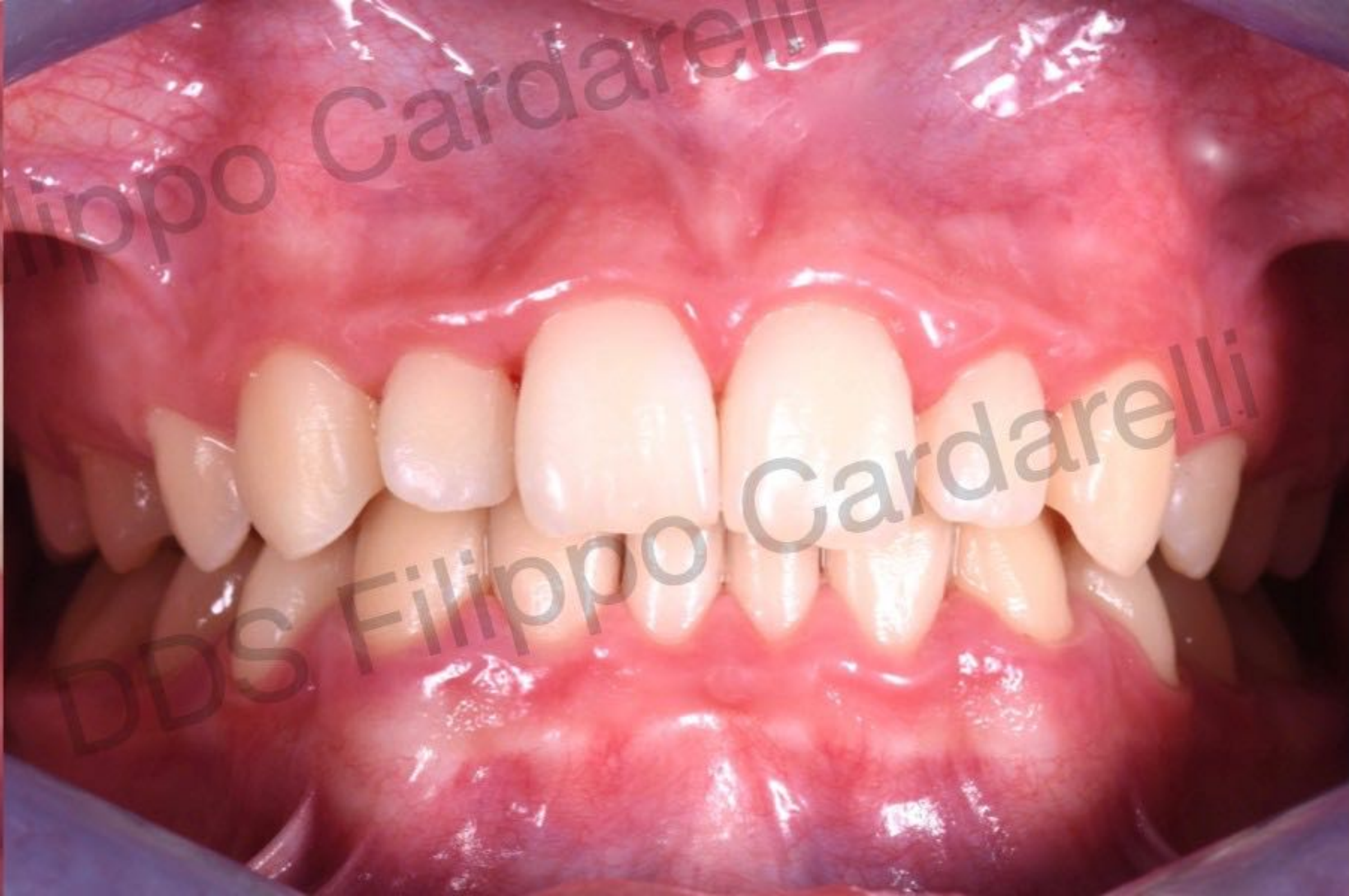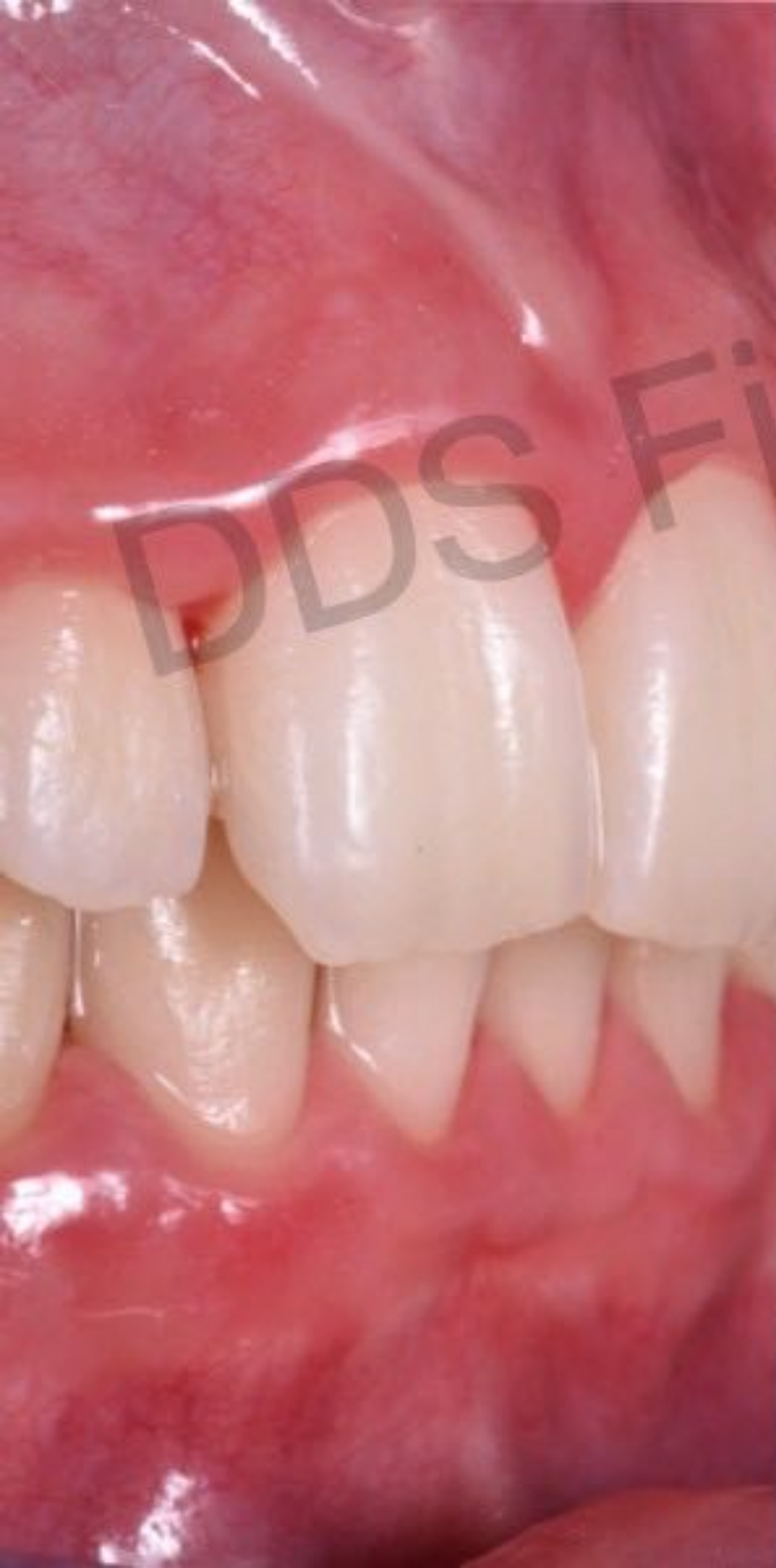09/16

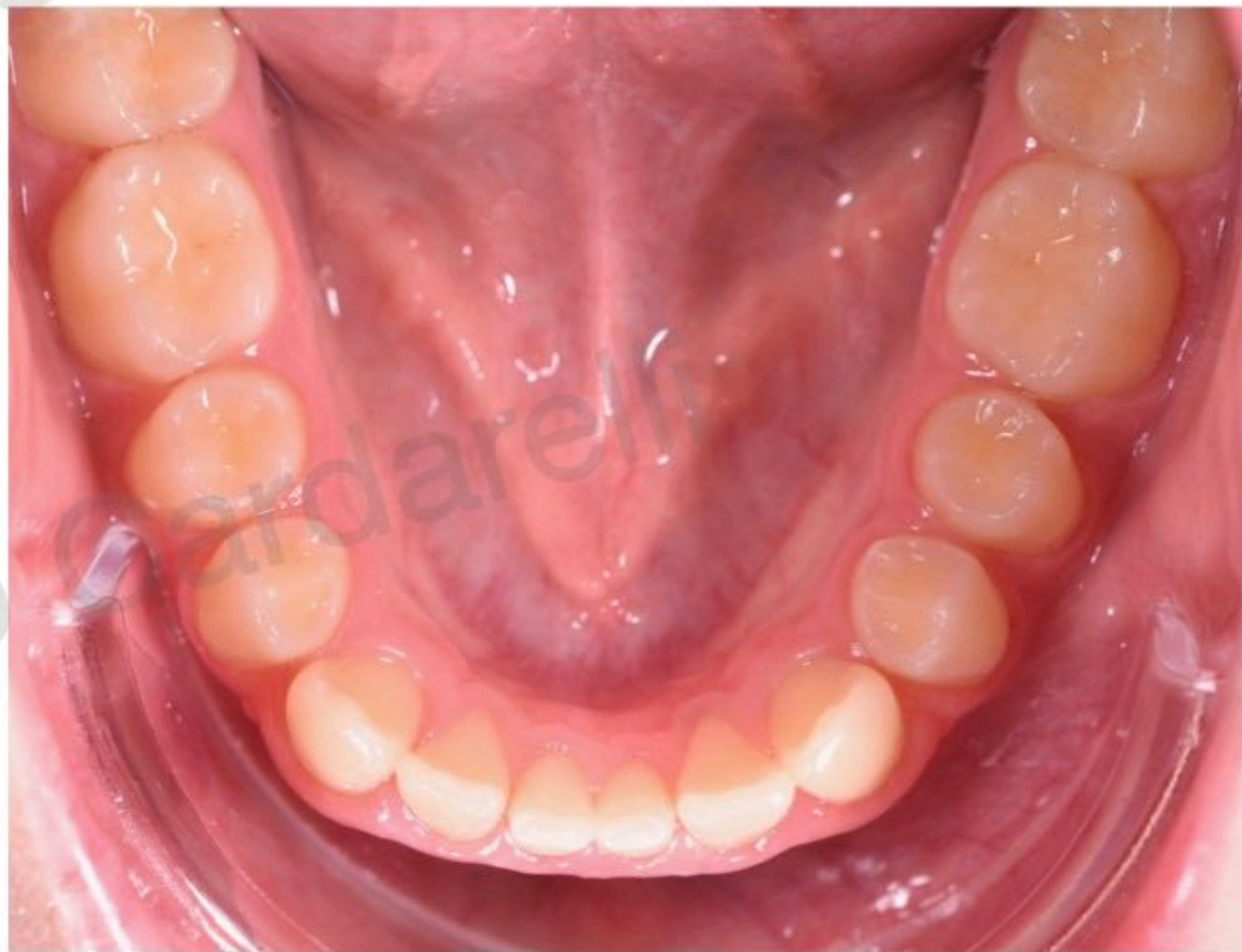
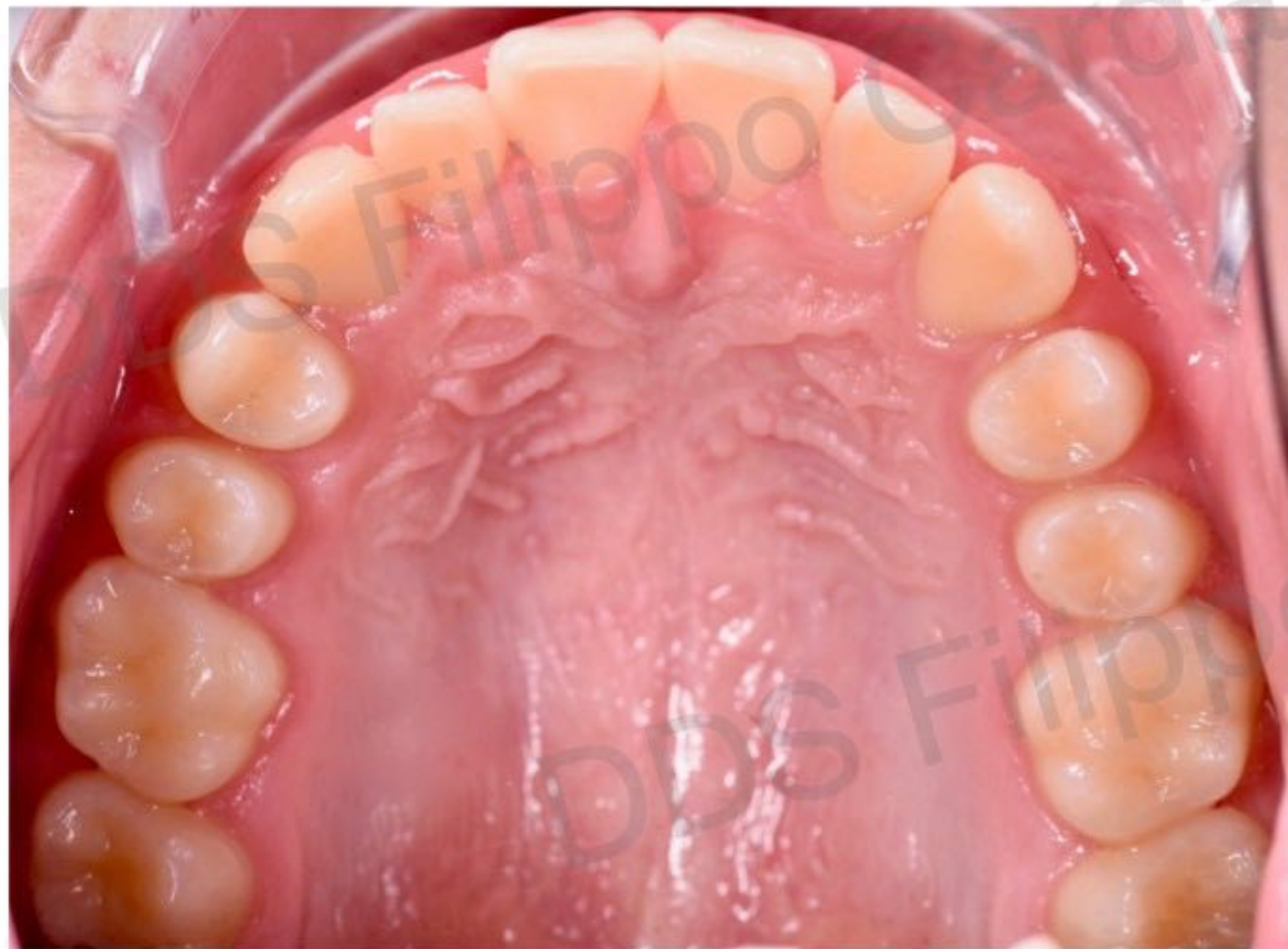
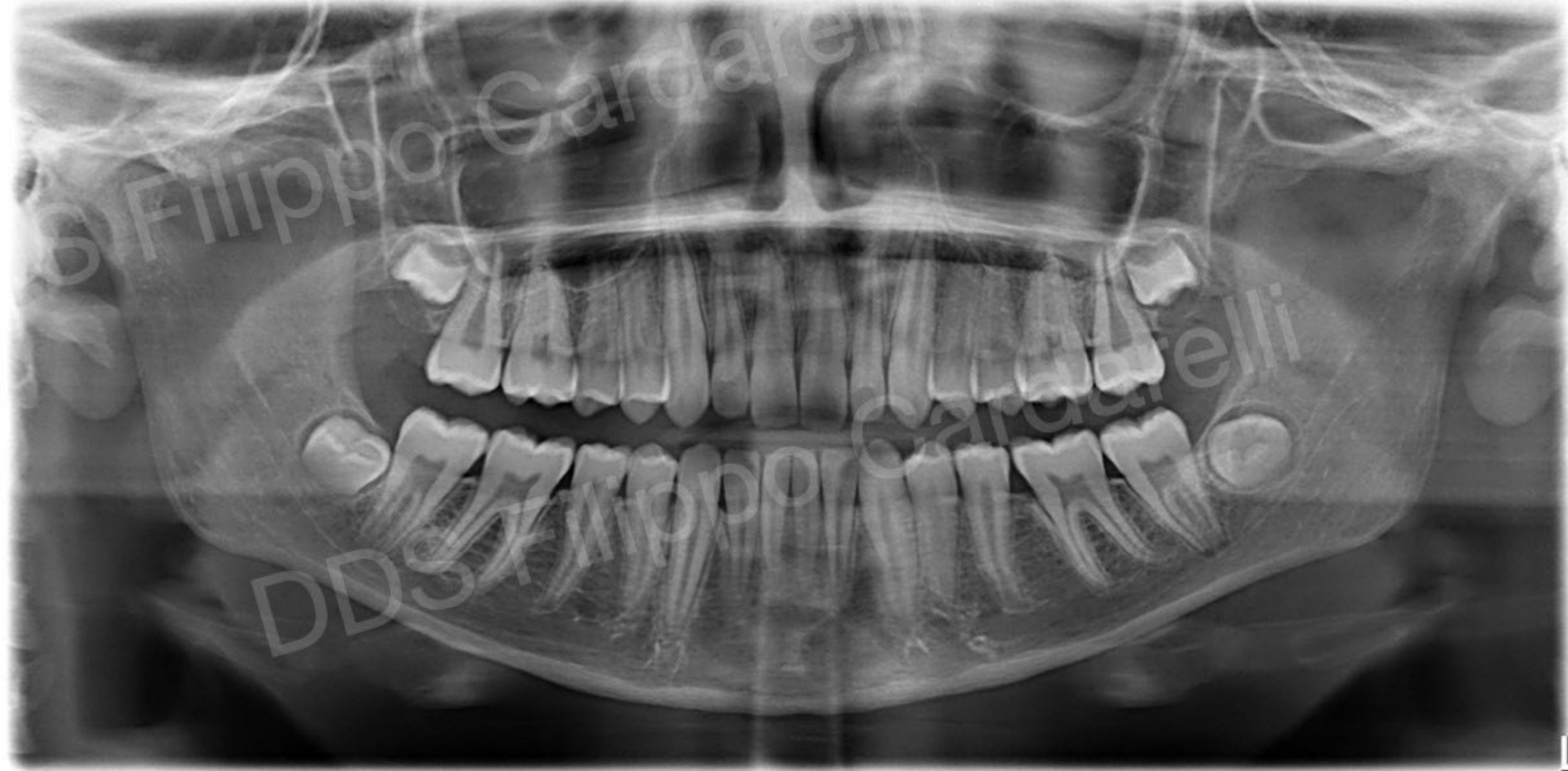08/18











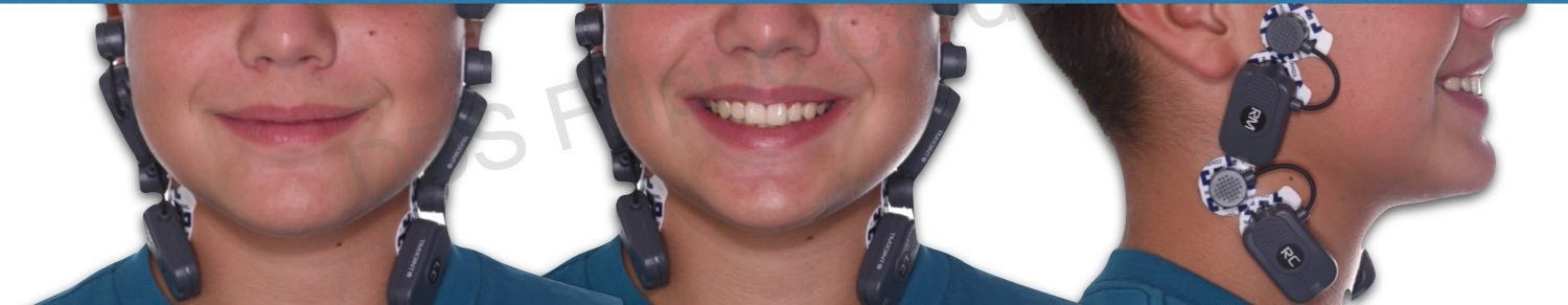Valori Cefalometrici Fine Trattamento

10mm

Cephalometric Values end of treatment

ANB	2,00	2,5
SNA	80,0	77,30
SNB	82,00	74,80
SArGo	140,0	142,0
ArGoMe	126,00	125,00
IiMand	85,20	89,20
IsCran	100,00	100,00
II	132,00	133,00

BTS TM JOINT



BTS TMJOINT REPORT

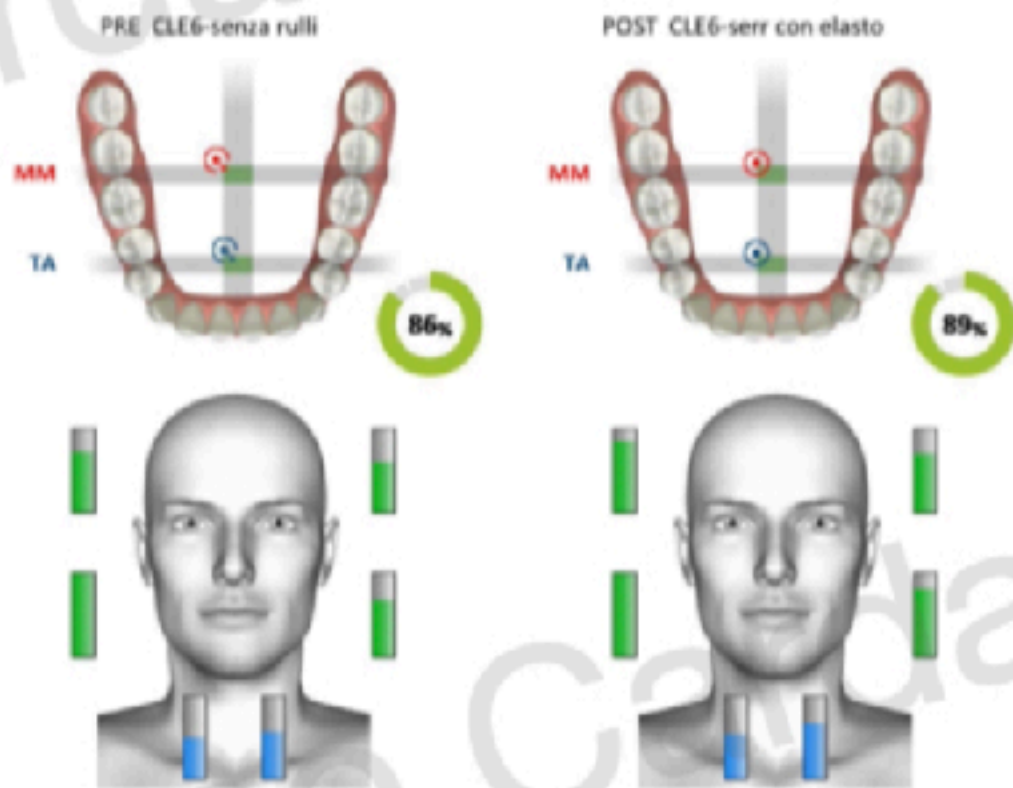
Valutazione dell'occlusione dentale

22/8/2018



Analisi del contatto dentale

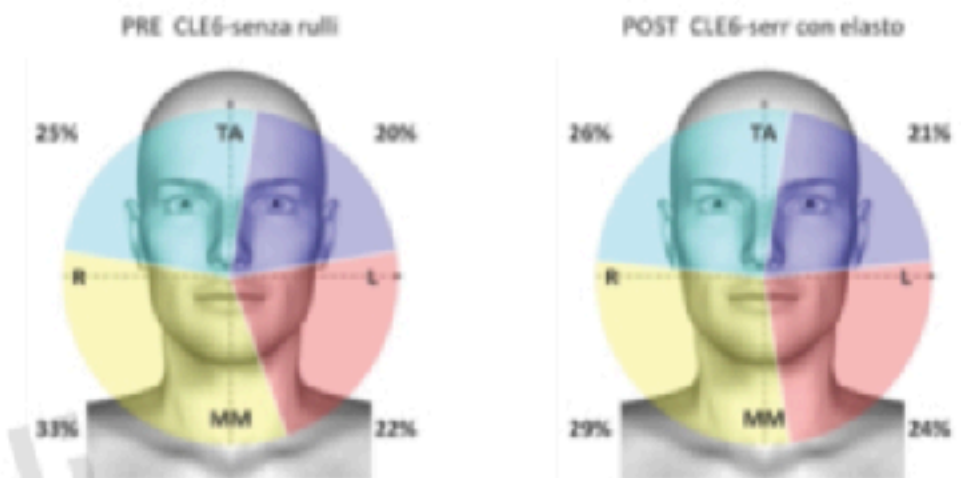
Nome: Riccio Eugenio
 Data di nascita: 22/9/2006
 Sesso: M
 Data del report: 22/8/2018
 Pagina: 2/3



INDICI	PRE		POST		NORMALITA'
POC TA	87.36%	Dx	85.45%	Dx	83s(%)s100
POC MM	79.68%	Dx	85.46%	Dx	83s(%)s100
BAR	87.66%	P	90.26%	P	90s(%)s100
TORS	89.69%	Sx	91.45%		90s(%)s100
IMP	191.83%		150.28%		85s(%)s115
ASIM	14.53%		9.60%		-10s(%)s10
POC SCM	86.48%	Sx	85.77%	Sx	83s(%)s100
CL	3.95%		3.57%		0s(%)s15

Analisi del contatto dentale

Nome: Riccio Eugenio
 Data di nascita: 22/9/2006
 Sesso: M
 Data del report: 22/8/2018
 Pagina: 3/3



CONCLUSIONI

PROVA PRE

Baricentro posteriore.
 Prevalenza temporali nella norma.
 Prevalenza masseteri destra.
 Prevalenza SCM nella norma.
 Asimmetria destra.
 Torsione sinistra.
 Lavoro muscolare prodotto alto.

PROVA POST

Baricentro nella norma.
 Prevalenza temporali nella norma.
 Prevalenza masseteri nella norma.
 Prevalenza SCM nella norma.
 Asimmetria nella norma.
 Torsione nella norma.
 Lavoro muscolare prodotto alto.

BTS TMJOINT REPORT



Conclusions

The deep bite malocclusion turns out to be corrected with the Amcop elastodontic appliance with Integral mastication plan, as is evident from the radiographic and photographic documentation but more importantly, at the end of the therapy an excellent muscle balance was obtained as can be seen from the final electromyographic examination.



DDS Filippo Cardarelli